

## Case Report

DOI: 10.62046/gijams.2025.v03i02.010

### Vogt-Koyanagi Harada Syndrome: A Case Report

Dhanisha JL<sup>1</sup>, Heber Anandan<sup>2</sup>, Preethi Anie E<sup>3</sup>, Jenisha Blessie K<sup>4</sup>, Kayal Vizhi A<sup>5</sup>

<sup>1</sup>Assoc. Professor & Principal, Dr. Agarwal's Institute of Optometry, Tirunelveli, Tamil Nadu, India

<sup>2</sup>Professor & Head of Academics, Dr. Agarwal's Institute of Optometry, Tirunelveli, Tamil Nadu, India

<sup>3</sup>Asst. Professor, Dr. Agarwal's Institute of Optometry, Tirunelveli, Tamil Nadu, India

<sup>4</sup>Lecturer, Dr. Agarwal's Institute of Optometry, Tirunelveli, Tamil Nadu, India

<sup>5</sup>PG Student, Dr. Agarwal's Institute of Optometry, Tirunelveli, Tamil Nadu, India

\*Corresponding Author: Heber Anandan | Received: 15.02.2025 | Accepted: 23.03.2025 | Published: 11.04.2025

**Abstract:** Vogt-Koyanagi-Harada (VKH) syndrome is an autoimmune disorder characterized by bilateral eye inflammation, which can also affect the skin and nervous system. This case report describes a 49-year-old female patient who presented with blurred vision in both eyes, accompanied by poliosis and unremarkable systemic health history. Initial examination revealed significantly reduced uncorrected visual acuity, and imaging techniques including optical coherence tomography (OCT) identified optic disc edema, sub retinal fluid, and choroidal folds in both eyes. Based on the findings, the patient was diagnosed with VKH syndrome and treated with corticosteroids, resulting in complete resolution after one month. This case highlights the importance of recognizing VKH syndrome, especially in patients presenting with atypical symptoms such as poliosis, to facilitate early diagnosis and intervention. Advanced imaging plays a crucial role in differentiating VKH from other conditions, ensuring effective management and monitoring to prevent potential relapse.

**Keywords:** Vogt-Koyanagi Harada Syndrome, Poliosis, Optic disc Edema, Choroidal folds, Sub-retinal Fluid.

**Citation:** Heber Anandan *et al.* Vogt-Koyanagi Harada Syndrome: A Case Report. Grn Int J Apl Med Sci, 2025 Mar-Apr 3(2): 88-91.

## INTRODUCTION

Vogt-Koyanagi-Harada (VKH) disease is a systemic autoimmune condition that primarily impacts pigmented tissues, with the most severe consequences affecting the eyes [1]. Characteristic histopathological features of VKH include granulomatous panuveitis, while the choriocapillaris remain unaffected, and patients may experience exudative retinal detachment [2]. In VKH, the immune response targets melanin-containing cells in the eyes, meninges, ears, and skin, particularly in individuals with genetic predispositions [3].

The initial phase of the disease often presents within days as an acute uveitic phase, marked by bilateral, typically symmetrical diffuse uveitis, along with noticeable hyperemia and edema of the optic disc, accompanied by varying degrees of serous retinal detachment. Inflammation can also affect the anterior segment, resulting in either granulomatous or nongranulomatous uveitis. Thickening of the uvea is notably pronounced in the posterior region, especially around the juxtapapillary choroid, with a gradual decrease towards the equatorial and peripheral choroid.

Notably, inflammatory cell infiltration generally spares the choriocapillaris and the adjacent retina. During the acute phase, retinal detachment may occur due to the accumulation of sub retinal fluid; however, such neurosensory detachment is uncommon during the recovery or chronic recurrent phases of VKH [4]. Additionally, some patients with Vogt-Koyanagi-Harada (VKH) disease who experience disc swelling have been observed to develop permanent visual field defects (VFD) during the acute stage of the condition. This has led to suggestions that they may be experiencing anterior ischemic optic neuropathy (AION) in conjunction with VKH [5]. Fluorescein angiography has revealed both delayed filling and later leakage at the optic disc, with persistent VFD noted even after the exudative retinal detachments and disc swelling have subsided. The use of optical coherence tomography (OCT) in both acute and chronic VKH cases has been extensively researched to inform immunotherapy decisions [6]. Furthermore, VKH patients with a choroidal thickness exceeding 550 µm at one-week post-onset have been reported to have a higher likelihood of early disease recurrence or progression to chronic conditions. [7] Systemic

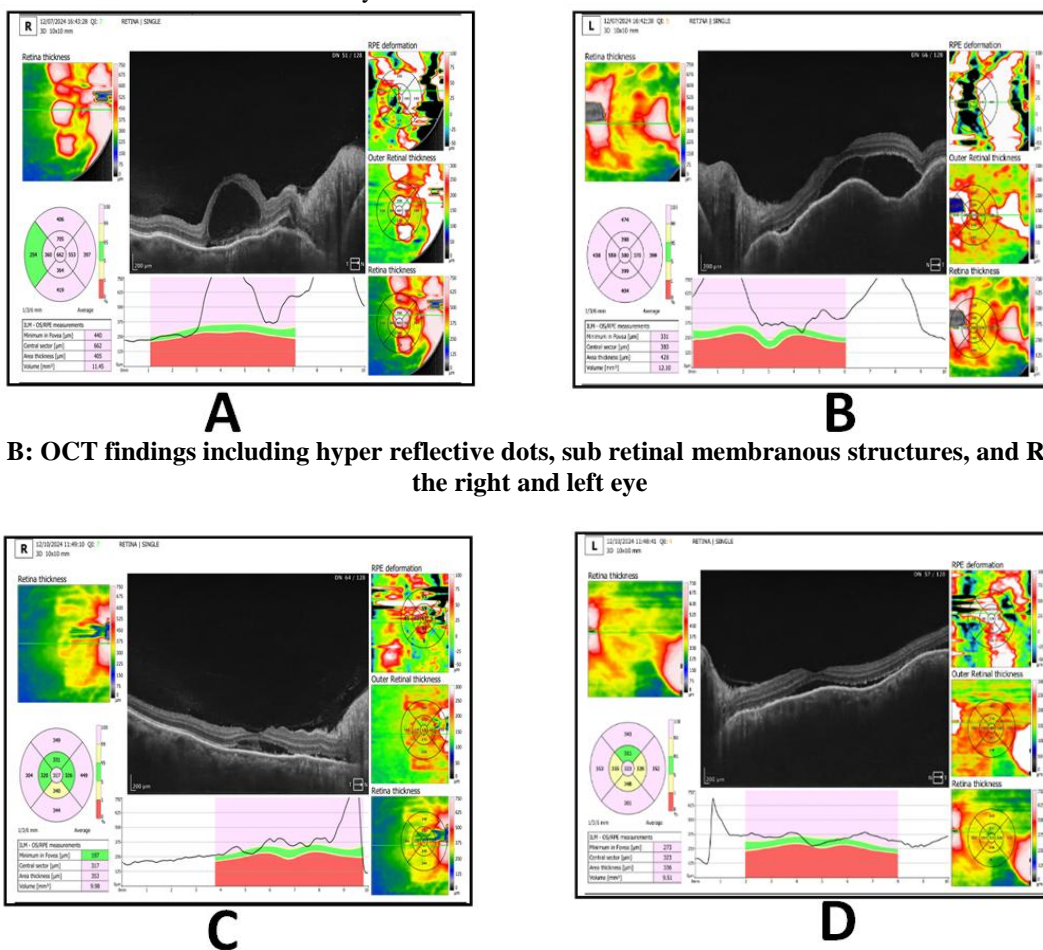
corticosteroid therapy has shown a rapid reduction in the severity of VKH symptoms [8]. Depigmentation of the choroid typically occurs over a period of 2 to 3 months, leading to a characteristic “sunset glow” appearance of the fundus, which is bright orange-red in color [9]. The presence of a sunset glow fundus in individuals with uveitis has a high positive predictive value of 94.5% for diagnosing Vogt-Koyanagi-Hard syndrome (VKH) and a negative predictive value of 89.2% [10]. This condition is more common in individuals with darker skin tones and tends to affect females more frequently, exhibiting a ratio of 2:1 compared to males [11].

The clinical progression of VKH can be categorized into three distinct stages: Stage 1, known as the prodromal stage, involves symptoms such as headache, fever, and photophobia, resembling a viral infection; Stage 2, referred to as the ophthalmic stage, includes bilateral uveitis, hypercubus, meningitis, and skin-related issues such as poliosis, vitiligo, and alopecia; and Stage 3, the convalescence stage, can persist for several weeks or even months, or it may become chronic [12].

**CASE SUMMARY**

This is a case report of a 49-year-old female patient who complained of blurred vision in both eyes for the

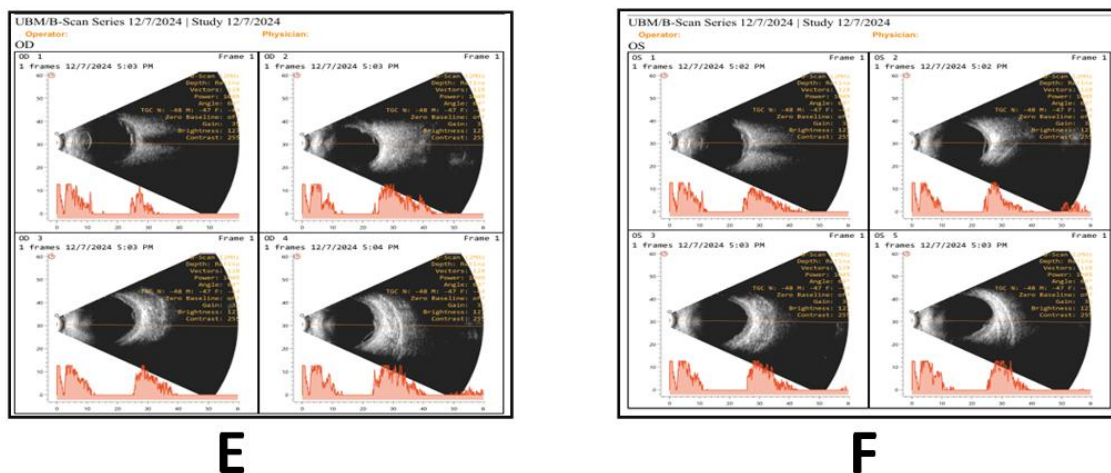
past three days. The patient had a history of using spectacles for five years, with her last prescription change occurring nine months ago. She had no reported systemic health issues or allergies. Notably, the patient exhibited signs of poliosis, characterized by white hair and white eyelashes, along with white patches on the skin near her eyes. Her uncorrected visual acuity was 6/60 in the right eye (RE) and 5/60 in the left eye (LE). With correction, the best-corrected visual acuity (BCVA) and pinhole (PH) vision were measured at 6/24P in the RE and +3.50DS in the LE. The near BCVA was recorded at N18, which she was able to read with +1.75DS. Slit lamp examination, B-scan and optical coherence tomography (OCT) of the macula revealed optic disc edema, subretinal fluid (SRF) collection, and choroidal folds in both eyes. Based on these evaluations, the patient was diagnosed with Vogt-Koyanagi-Harada syndrome affecting both eyes. The treatment included Wysolone tablets and PredForte eye drops, which comprised tapering steroids administered to both eyes over one month. After one month of follow-up, the patient's Vogt-Koyanagi-Harada syndrome was resolved. The differential diagnosis includes sympathetic ophthalmia, choroidal melanoma, infectious posterior uveitis, Alport and Cogan syndromes, sarcoidosis, and systemic lupus erythematosus chorioretinopathy.



**Figure-A, B: OCT findings including hyper reflective dots, sub retinal membranous structures, and RPE folds in the right and left eye**

**Figure-C, D: Resolved hyper reflective dots and structures in right and left eye**





**Figures-E, F: B-scan demonstrating diffuse thickening of the posterior choroid with low to medium reflectivity in the right and left eye**

## DISCUSSION

Edmund Tsui *et al.* reported a case of unilateral VKH disease in which they treated VKH by corticosteroids [10]. Soon-Phaik Chee *et al.* [12] reported that OCT plays a major role in prognosis of VKH. They concluded OCT helps in finding optic disc swelling, choroidal folds, hyper reflective dots, subretinal membranous structure, RPE folds and RD in VKH patients. In our case report it emphasizes the need to recognize Vogt-Koyanagi-Harada (VKH) syndrome, especially in patients with unusual symptoms like poliosis. VKH is an autoimmune disorder that causes bilateral eye inflammation, and it can affect the nervous system and skin. The patient blurred vision and findings like optic disc swelling highlight the importance of early diagnosis. Poliosis may indicate an autoimmune process or genetic predisposition. It is essential to conduct thorough evaluations to rule out other conditions, such as sympathetic ophthalmia or infections. Advanced imaging techniques like Optical Coherence Tomography (OCT) can help differentiate these issues. The patient's rapid improvement with corticosteroid treatment demonstrates the effectiveness of this therapy for VKH syndrome, making close post-treatment monitoring crucial to prevent relapse.

## CONCLUSION

This case underscores the importance of timely diagnosis of VKH syndrome in patients with unusual eye symptoms. Understanding the link between autoimmune responses and eye health enables better management. The positive response to corticosteroids highlights the need for early intervention, and regular follow-ups are vital for maintaining patient health and vision.

## REFERENCES

- O'Keefe GA, Rao NA. Vogt-Koyanagi-Harada disease. *Surv Ophthalmol.* 2017 Jan-Feb;62(1):1-25.
- Golzari MF, Cheja-Kalb R, Concha-Del-Río LE, Gonzalez-Salinas R, Arellanes-García L. Risk factors for subretinal fibrosis in patients with Vogt Koyanagi Harada syndrome. *Ocul Immunol Inflamm.* 2022 Feb 17;30(2):265-269.
- Herbert CP, Mochizuki M. Vogt-Koyanagi-Harada disease: inquiry into the genesis of a disease name in the historical context of Switzerland and Japan. *Int Ophthalmol.* 2007 Apr-Jun;27(2-3):67-79.
- Mochizuki M. Regional immunity of the eye. *Acta Ophthalmol.* 2010 May;88(3):292-9.
- Albalawi AM, Al-Barry MA. Genetic variations in autoimmune genes and VKH disease. *Int Ophthalmol.* 2020 Nov;40(11):3175-3186.
- Yang P, Zhong Y, Du L, Chi W, Chen L, Zhang R, Zhang M, Wang H, Lu H, Yang L, Zhuang W, Yang Y, Xing L, Feng L, Jiang Z, Zhang X, Wang Y, Zhong H, Jiang L, Zhao C, Li F, Cao S, Liu X, Chen X, Shi Y, Zhao W, Kijlstra A. Development and Evaluation of Diagnostic Criteria for Vogt-Koyanagi-Harada Disease. *JAMA Ophthalmol.* 2018 Sep 01;136(9):1025-1031.
- Ishikawa A, Shiono T, Uchida S. Vogt-Koyanagi-Harada disease in identical twins. *Retina.* 1994;14(5):435-7.
- Herbert CP, Tugal-Tutkun I, Abu-El-Asrar A, Gupta A, Takeuchi M, Fardeau C, Hedayatfar A, Urzua C, Pappasavvas I. Precise, simplified diagnostic criteria and optimised management of initial-onset Vogt-Koyanagi-Harada disease: an updated review. *Eye (Lond).* 2022 Jan;36(1):29-43.
- Park JG, Callaway NF, Ludwig CA, Mahajan VB. Intravitreal methotrexate and fluocinolone acetonide implantation for Vogt-Koyanagi-Harada uveitis. *Am J Ophthalmol Case Rep.* 2020 Sep;19:100859.
- Tsui, E., Bottini, A., Ghadiali, Q., Balaratnasingam, C., & Barbazetto, I. (2018).



- Unilateral Ocular Manifestations of Vogt-Koyanagi-Harada Disease. *Ocular immunology and inflammation*.
11. Nakao, K., Abematsu, N., Mizushima, Y., & Sakamoto, T. (2012). Optic disc swelling in Vogt-Koyanagi-Harada disease. *Investigative ophthalmology & visual science*, 53(4), 1917-22.
  12. Chee, S. P., Afrin, M., Tumulak, M. J., & Siak, J. (2021). Role of Optical Coherence Tomography in the Prognosis of Vogt-Koyanagi-Harada Disease. *Ocular immunology and inflammation*, 29(1), 118–123.

