

Traumatic Rupture of the Diaphragm About 19 Cases

Khalil Ghebouli^{1*}, Karim Meskouri¹, Nadjib Mebarki¹, Youcef Khanchoul², Badis Foughali³

¹Department of Thoracic Cardiovascular and Organ Transplantation, University hospital Mustapha, Algiers, Algeria

²Department of General Surgery A. University hospital Ibn Badis, Constantine, Algeria

³Department of Reanimation University hospital Ibn Badis, Constantine, Algeria

*Corresponding Author: Khalil Ghebouli

| Received: 06.01.2024 | Accepted: 02.03.2024 | Published: 12.04.2024

Abstract: Traumatic ruptures of the diaphragm (TRD) are serious lesions that are often part of polytrauma. The diagnosis of wounds and diaphragmatic rupture remains difficult and often delayed. **Methods:** We conducted a descriptive observational study with retrospective data collection. It took place in two referral hospitals in Algeria. **Results:** Our study involved 19 cases of diaphragmatic injuries. The sex-ratio was 8.5. The mean age was 29 years. Traffic accident represented 78.95%. The diaphragmatic rupture was on the left side in 84.21 % (16 cases). The surgical procedure involved a reduction of herniated viscera and a suture of the diaphragm by "X" non absorbable points in 73.68 % (15 cases). The evolution was favorable in all patients, except one death. **Conclusion:** A diaphragmatic rupture is often integrated into a polytrauma, of which it is a criterion of Severity; however the diagnosis may be overlooked in the acute phase because it poses a real diagnostic and therapeutic challenge.

Keywords: Diaphragm, Thoracoabdominal trauma, Surgery, Suture

Citation: Khalil Ghebouli *et al.* Traumatic Rupture of the Diaphragm About 19 Cases. Grn Int J Apl Med Sci, 2024 Mar-Apr 2(2): 53-57.

INTRODUCTION

Traumatic rupture of the diaphragm TRD corresponds to a breach which communicates the abdominal with the thoracic cavity. It must systematically be mentioned during thoracic or abdominal trauma for which it is a serious criterion [1]. A rupture of the diaphragm is present in 0.2 to 4% of trauma patients hospitalized for a thoracic and/or abdominal contusion [2-4]. However, it can be discovered immediately during the early phase of the accident or very late, sometimes years later due to the fact that intra-thoracic penetration of the abdominal viscera does not always occur immediately following the diaphragmatic rupture [5].

Once diagnosed, surgical treatment via the abdominal or thoracic approach is necessary. The laparoscopy approach is legitimate in a stable trauma patient.

MATERIELS AND METHODS

This was a descriptive observational study with retrospective data collection. It took place in two referral hospitals in Algeria, department of thoracic and cardiovascular surgery of Algiers and the department of thoracic surgery of Constantine. We included the records of all patients who underwent surgery for a

traumatic rupture of the diaphragm between January 1, 2017 and December 31, 2022. The data was collected using a previously established survey form. The study variables were: socio demographic characteristics of the patients, mechanism and type of injury, surgical technique and postoperative outcome within 30 days of surgery.

RESULTS

Our study included 19 cases of diaphragmatic rupture. They were 17 men and 2 women with a sex ratio of 8.5. The average age was 29 years, with extremes of 19 and 38 years. For 18 patients, the mean time to admission was 2.7 days with extremes of 1 h and 10 days. For one patient, the admission's period was 18 years after a chest stab wound drained. The circumstances were a traffic accident in 15 cases (78.95 %) and a penetrating wound in 4 cases (21.05 %). In the 15 cases of contusion, the trauma was strictly thoracic in 8 cases (53.33%), strictly abdominal in 5 cases (33.33%) and thoracoabdominal in 2 cases (13.33%).

In the 5 cases of penetrating wounds, the invading agent was a stab wound in 3 cases (60%) and an arrow in 2 cases. The TRD was on the left in 16 cases (84.21%), on the right in three cases (15.79%) and we did not observe a bilateral rupture.

In 13 cases (68.42%), the TRD was part of a polytrauma. The most frequent associated lesions were digestive (n = 10) and bone (n = 3). The most frequent visceral injury was a splenic wound (n = 4).

The assessment included a chest x-ray (100%), which showed ascent of the diaphragmatic dome left (63.16%) (Figure 1), ascent of the diaphragmatic dome right (10.53%), gaseous clarity in the left hemithorax (10.53%), basal opacity left (15.79%).

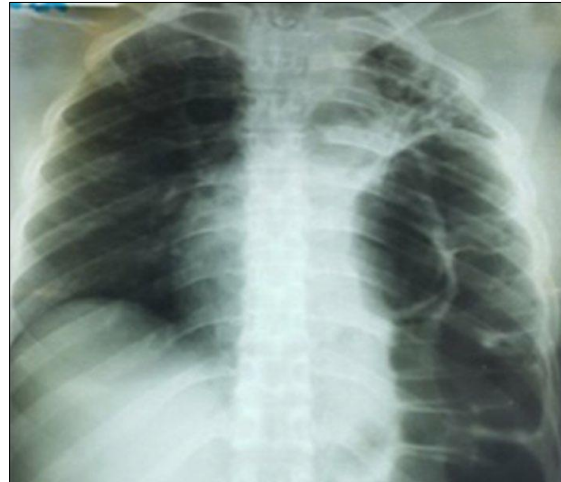

Figure 1: chest x-ray showing left diaphragmatic rupture with ascension of the stomach and left colon

Abdominal ultrasound was performed in (57.89%) and showed peritoneal effusion in 4 patients. Abdomen x-ray without preparation was performed in (57.89%) showed hydroaeric levels (HAL) hial colic in 6 patients (31.58%), small intestine HAL in one patient and intestinal and colic distension in one case.

After the first resuscitation measures were made, only 12 patients were able to perform Thoraco abdominal CT scan and showed ascension of viscera abdominals in the left hemithorax which are, in order of frequency, the stomach (75%), the small intestine (41.66%) and the colon (25%) (Figure2 and 3).

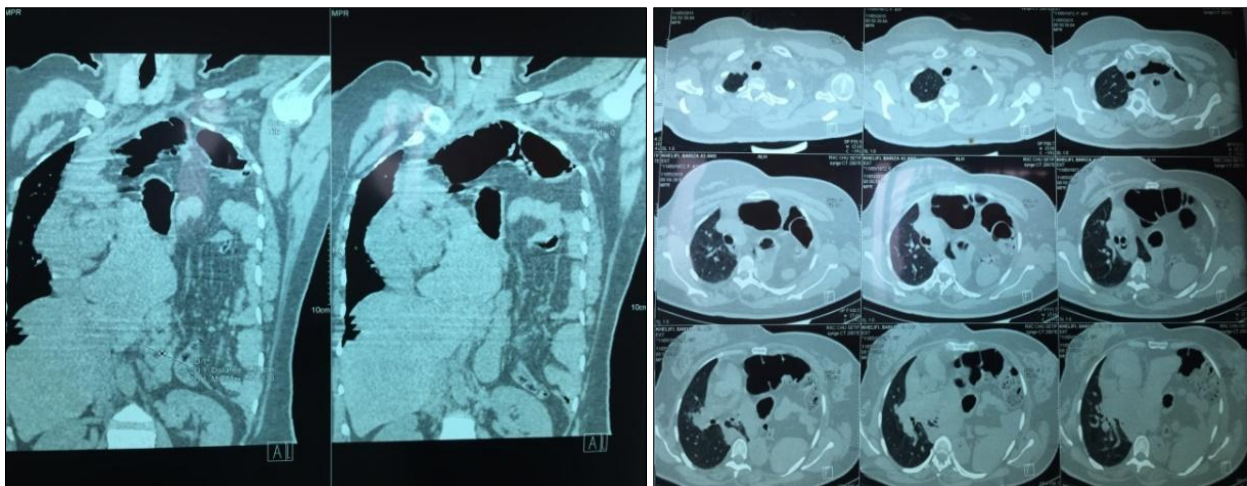


Figure 2 and 3: CT scann showing left diaphragmatic rupture with ascension of the stomach and left colon

All patients were operated on under general anaesthesia with orotracheal intubation. 13 patients were operated on by laparotomy; in 3 cases (15.79%), this laparotomy was associated with a left posterolateral thoracotomy. 4 patients were operated by

videothoracoscopy and 2 patients by posterolateral thoracotomy (Figure 4). The dimensions of Diaphragmatic ruptures vary between 5- 10cm in 68.42% of patients. They were less than 5 cm in 3 patients and greater than 10 cm (15.79%) in 3 patients.

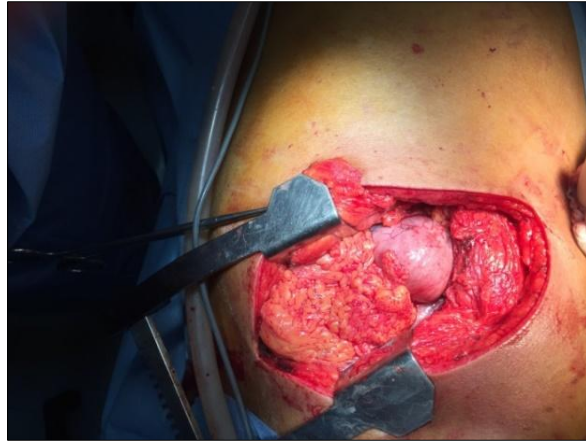


Figure 4: Left posterolateral thoracotomy. Note the exit of the digestive organs through the incision

The surgical procedure consisted in a reduction of herniated organs, repair of the diaphragm rupture by “X” suture using an absorbable thread in

73.68 % (15 cases) (Figure 5) and «paletot» suture in 15.79 %. A prosthetic cure was performed in two cases (Figure 6).

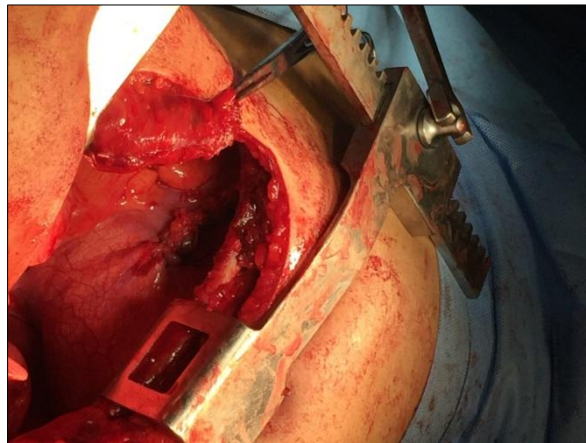


Figure 5: reparation for diaphragmatic rupture by direct suture

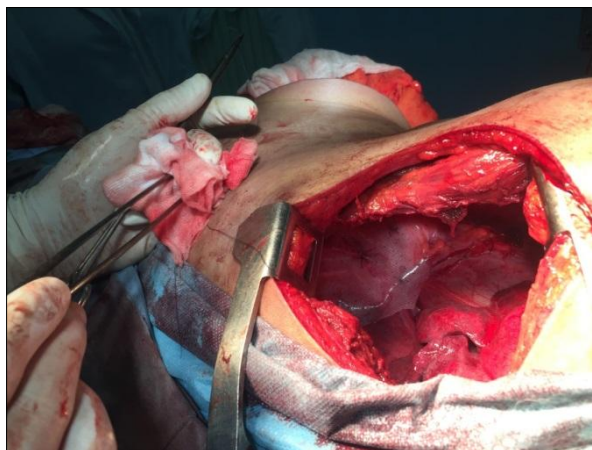


Figure 6: reparation for diaphragmatic rupture by prosthetic cure

Thoracic drainage was performed in all cases. The mean duration of thoracic drainage was 3 days, with extremes of 2 days and 7days. The mean hospital stay was 6 days with extreme of 4 and 10 days.

Mortality rate was 5.26 %. One patient died of third sector syndrome. It was an old diaphragmatic rupture occurring in childhood following a traffic accident and discovered 18 years later by respiratory distress.

Morbidity rate was two cases (10.53%). It was one case of lung atelectasis, with uneventful course. One case of recurrence was noted 8 months after diaphragmatic thoracoscopic suture. It was treated with a composite prosthesis by open surgery.

DISCUSSION

The epidemiological study finds that the rupture of the diaphragm is most often a lesion in young adult males [6, 7], which is consistent with the results of our study. Traumatic rupture of the diaphragm can be caused by two mechanisms: contusion (encountered in traffic accidents), or by wound. Traffic accidents represent the primary cause of ruptures of the diaphragm in the different series, including ours. They are 3 times more frequent on the left than on the right [2], due to the presence on the right of the liver which is a fixed organ and has a protective role [1]. In addition, right ruptures are often associated with vital lesions (liver, suprahepatic veins, inferior vena cava), causing death before arrival of the injured person to the hospital [6]. Likewise bilateral extend to the two domes are exceptional in survivors, because they are secondary to very violent trauma [8]. In our series, the diaphragmatic rupture occurs located at the left dome at 84.21% and we did not observe bilateral rupture. The size of the diaphragmatic rupture is on average a ten centimeters [9]. In our series, the most diaphragmatic ruptures are large size (84.21%) varying between 5 and more than 10cm. The natural evolution of the rupture diaphragmatic is done towards a passage almost inevitable from the viscera towards the thorax at more or less long term [6]. Migrations visceral disorders mainly affect the left dome and are mainly polyvisceral.

Diagnosis of diaphragmatic rupture is still late; in 18 to 50% of cases, it is only placed at a distance from the causal trauma [5]. Radiological examinations are essential to confirm the diagnosis. In our study, chest radiography was contributory to diagnosis of wounds and diaphragmatic in rupture in 63.16 % of cases. Abdominal ultrasound is important for abdominal injury assessment [10]. Abdominal CT scan has a good diagnostic sensitivity in wounds and diaphragmatic ruptures, but it must be done on stable patients. The best way to make the faster diagnosis of diaphragmatic injury is to evocate it systematically facing contusion and/or thoracoabdominal penetrating wound. Thoracoscopy and laparoscopy have both a double interest: diagnostic and therapeutic. After the diagnosis of a diaphragmatic lesion, the repair must be carried out as soon as possible.

The choice of the surgical approach is controversial, due to the non-operative therapies approach and minimally invasive surgery. However, if the patient is in unstable hemodynamic state, emergency laparotomy is indicated in the event of rupture left diaphragmatic and thoracotomy in case of

right side [11]. If the patient is stable on the hemodynamic state, surgery can be more or less delayed. She may be performed by videoscropy: thoracoscopy is especially indicated for right side and laparoscopy in case of left rupture [11]. The surgical procedure consisted in a reduction of herniated organs; repair of the diaphragm rupture by "X" suture using an absorbable thread. During of a loss of substance, a plastic surgery can be used [12].

In our study, the diaphragmatic breach was mostly repaired by laparotomy (68.42%). Indeed, this approach seems to us to be sufficient to reduce the often associated diaphragmatic hernia, treat the associated visceral digestive injuries and close the diaphragmatic breach. A combined approach (laparotomy and thoracotomy) was performed in three cases, due to the impossibility of integration intra-abdominal viscera. Post-operative procedures are often simple; the prognosis is not dire in itself. There severity is linked to the associated lesions. There mortality of trauma victims of rupture of the diaphragm is estimated between 20 and 60%. This mortality is most often due to associated lesions [1]. In our series, the evolution was favorable in all patients, except one patient who died of third sector syndrome. It was an old diaphragmatic rupture occurring in childhood following a traffic accident and discovered 18 years later by respiratory distress. Intra-abdominal reintegration of the digestive organs was impossible given their significant development in relation to the volume of the abdominal cavity.

CONCLUSION

Diaphragmatic rupture occurs in major blunt trauma; it is a marker of severe injury. Traumatic rupture of diaphragm must be systematically kept in mind in case of violent closed thoraco-abdominal trauma or in case of basithoracic wound. A diagnosed diaphragmatic rupture constitutes an indication for surgery. Whatever the thoracic or abdominal approach, the surgical treatment is based on the reintegration of the digestive organs and the suture of the breach by direct suture or the installation of a prosthesis.

Conflict of Interesting: None

REFERENCE

1. Favre, J. P., Cheynel, N., Benoit, L., & Favoulet, P. (2005). Traitement chirurgical des ruptures traumatiques du diaphragme. *EMC-chirurgie*, 2(3), 242-251. doi: 10.1016/j.emcchi.2005.04.004.
2. Boulanger, B. R., Milzman, D. P., Rosati, C., & Rodriguez, A. (1993). A comparison of right and left blunt traumatic diaphragmatic rupture. *Journal of Trauma and Acute Care Surgery*, 35(2), 255-260.
3. Goudet, P., Cheynel, N., Ferrand, L., Peschaud, F., Steinmetz, J. P., Letourneau, B., ... & Cougard, P.



- (2001). Lateral approach to laparoscopic repair of left diaphragmatic ruptures. *World journal of surgery*, 25(9), 1150-1154.
4. Guth, A. A., Pachter, H. L., & Kim, U. (1995). Pitfalls in the diagnosis of blunt diaphragmatic injury. *The American journal of surgery*, 170(1), 5-9.
 5. Takongmo, S., NKO'O AMVENE, S., Juino, A. G., Nkam, M., & Malonga, E. (1993). Les hernies diaphragmatiques post-traumatiques: à propos de trois observations récentes. *Médecine d'Afrique noire*, 40(1), 42-46.
 6. Andreassian, B., & Salmon, R. (1980). Rogerew. Problèmes diagnostiques et thérapeutiques des ruptures traumatiques récentes du diaphragme. A propos de 37 cas. *Ann Chir*, 34, 284-289.
 7. Neidhart, J. P., & Caillot, J. L. (1997). Ruptures du diaphragme dans les traumatismes fermés. *La revue du Praticien*, 47, 971-975.
 8. Osmak, L., & Cougard, P. (2003). Diaphragmatic hernia. *La Revue du praticien*, 53(15), 1683-1687.
 9. Ammann, A. M., Brewer, W. H., Maull, K. I., & Walsh, J. W. (1983). Traumatic rupture of the diaphragm: real-time sonographic diagnosis. *American Journal of Roentgenology*, 140(5), 915-916.
 10. Kafih, M., & Boufettal, R. (2009). Post-traumatic diaphragmatic hernia revealed by stercoral pleurisy (about a case). *Journal of Clinical Pneumology*, 65 (1), 23-26.
 11. Giudicelli, R., Lecuyer, T., Velly, J., Grosdidier, G., Heyd, B., D'journo, B., ... & Jancovici, R. (2006). Les ruptures diaphragmatiques post traumatiques; Place de la chirurgie mini-invasive. *Em émoires de l'Académie Nationale de Chirurgie*, 5, 5-10.
 12. Blumenthal, D. H., Raghu, G., & Rudd, T. G. (1984). Diagnostic of right hemidiaphragmatic rupture by liver scintigraphy. *J Trauma*, 24, 536-538.