

Research Article

DOI: 10.62046/gijams.2024.v02.i05.005

The Relationship between Impacted Mandibular Third Molar and Mandibular Canal on Orthopantomogram – A Retrospective Study

Nazih Shaban Mustafa^{1*}, Omar Abdul Jabbar AbdulQadir², Sayfaldeen Kashmoola³, Dr. Engku Musfirah Che Ku Abdullim⁴, Dr. Nur Izzah Che Mohd Hashim⁴

¹Associate Professor, Department of Oral Maxillofacial & Oral Diagnosis KOD, IIUM, Malaysia

²Assistant Professor, Department of Oral & Maxillofacial Pathology, Faculty of Dentistry, Al- Mashreq University, Baghdad, Iraq

³Lecturer, Faculty of Dentistry, Qaiwan International University, Sulaymaniyah, Iraq

⁴Dental Officer Ministry of Health Malaysia

*Corresponding Author: Nazih Shaban Mustafa | Received: 19.08.2024 | Accepted: 15.09.2024 | Published: 04.10.2024

Abstract: Background: Surgical removal of the impacted lower third molar teeth require thorough investigations and assessment, one of these very important investigations is orthopantomogram (OPG) which is the primary assessment method, to determine the relationship between impacted mandibular third molar and mandibular canal. The study aims to determine the relationship between impacted mandibular third molar and mandibular canal on orthopantomogram. **Materials and methods:** A retrospective of 300 OPGs out of 947 OPG were selected using simple random sampling method. Rood's criteria was used in assessing the relationship between the apex of the roots and upper border of the inferior alveolar canal. Statistical analysis was performed to assess the relationship between the canal and the impacted lower third molar in relation to the age, gender and type of impaction. **Results:** From 300 OPG, 473 impacted teeth were identified, the relation showed, the highest percentage was superimposed with 47.3%, followed by close contact (35.7%), and only 21.7% of the impacted teeth examined has distance between the roots and the upper border of mandibular canal. **Conclusion:** Mesioangular impaction has higher percentage of superimposition with the mandibular canal with the higher percentage of female 58% to male 42% ratio.

Keywords: lower third molar, mandibular canal, impacted, orthopantomogram, retrospective.

Citation: Nazih Shaban Mustafa *et al.* The Relationship between Impacted Mandibular Third Molar and Mandibular Canal on Orthopantomogram—A Retrospective Study. Grn Int J Apl Med Sci, 2024 Sep-Oct 2(5): 203-210.

INTRODUCTION

Impacted tooth is defined as any tooth that is prevented from reaching its normal position in the mouth either by soft tissue, bone, or another tooth [1]. The most common impacted teeth in adults are the mandibular third molars which frequently require surgical extraction [2]. Unfortunately, postoperative complications usually will arise following this procedure. For that reason, there are certain indications and contraindications that we need to refer to before any procedure of surgical removal of third molar is carried out. According to the latest National Institute for Health and Care Excellence (NICE) guidelines, surgical removal of impacted third molars should be limited to patients with evidence of pathology only. Functional tooth deeply impacted tooth with no signs and symptoms, and exposure to high risk of surgical and medical complications are contraindicated to be removed [3].

MATERIALS AND METHOD

A retrospective of 300 OPGs out of 947 OPG were selected using simple random sampling method. Rood's criteria was used in assessing the relationship between the apex of the roots and upper border of the canal. Statistical analysis was performed to assess the relationship between the variables.

All OPG were retrieved and selected based on inclusion and exclusion criterias. The criterias were as follow;

Inclusion criteria

- Impacted, partially erupted mandibular third molar with fully formed root
- Good quality OPG

Exclusion criteria

- History of facial trauma
- Mandible with pathologic lesions such as cyst, tumour, etc.

• OPG with incomplete data and in bad quality
Each OPG was categorized according to gender group, age group, type of impaction and relationship to MC. The relationship between apices of wisdom tooth and

mandibular canal was classified as distance, close relationship and superimposition as shown in figure 1,2&3.

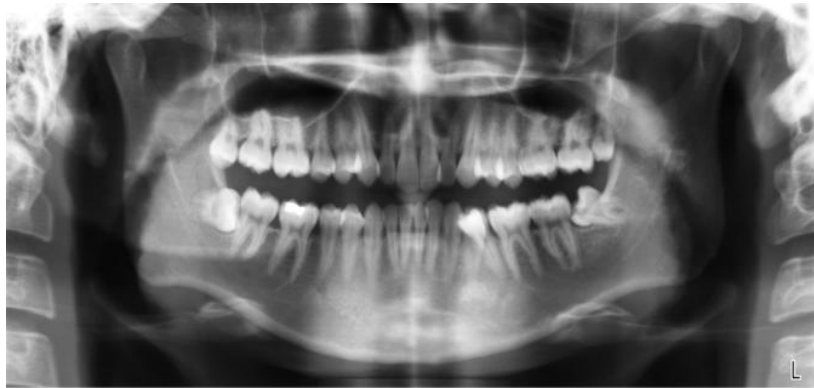

Figure-1: Distance (away from the mandibular canal)

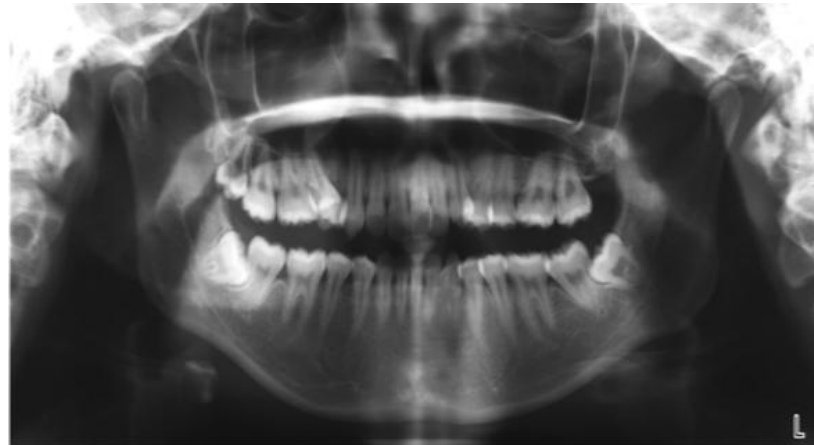


Figure-2: Close relation

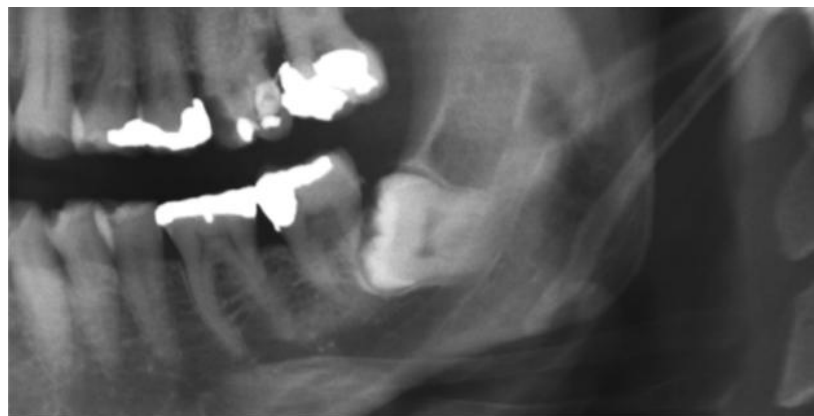


Figure-3: Superimposition

The measurements were done by using digital caliper of Romexis Software, the average readings were taken, and the data was recorded.

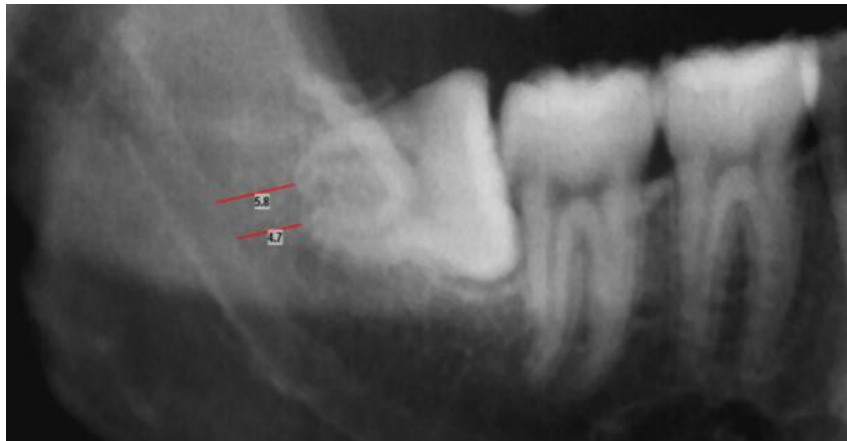

Figure-4: Measurement of the distance between the apices of the impacted tooth and the MC

The data analysis was carried out by using SPSS 23. Then the mean distance was calculated. Statistical analysis (X² test) was used to determine the association between the predictor and the outcome variables. Probability (p) values less than 0.05 were considered statistically significant.

RESULTS

From the OPGs collected , there were 46% are male and 54% are female. The age groups were divided into 20-29 years old (72%), 30-39 years old (22%), and 40-49

years old (6%). 56% have both sidedimpaction, for right side impaction, there were horizontal (21%), vertical (12%), mesioangular (39%), distoangular (6%) and no impaction (22%). For left side impaction, there were horizontal (25%), vertical (15%), mesioangular (27%), distoangular (9%) and no impaction (21%). In right sided impaction, the most common radiographical findings showed the presence of distance (51 roots) and contact (45 roots). For left sided impaction, the most common radiographical findings were superimposed (55 roots) and distance (47 teeth).

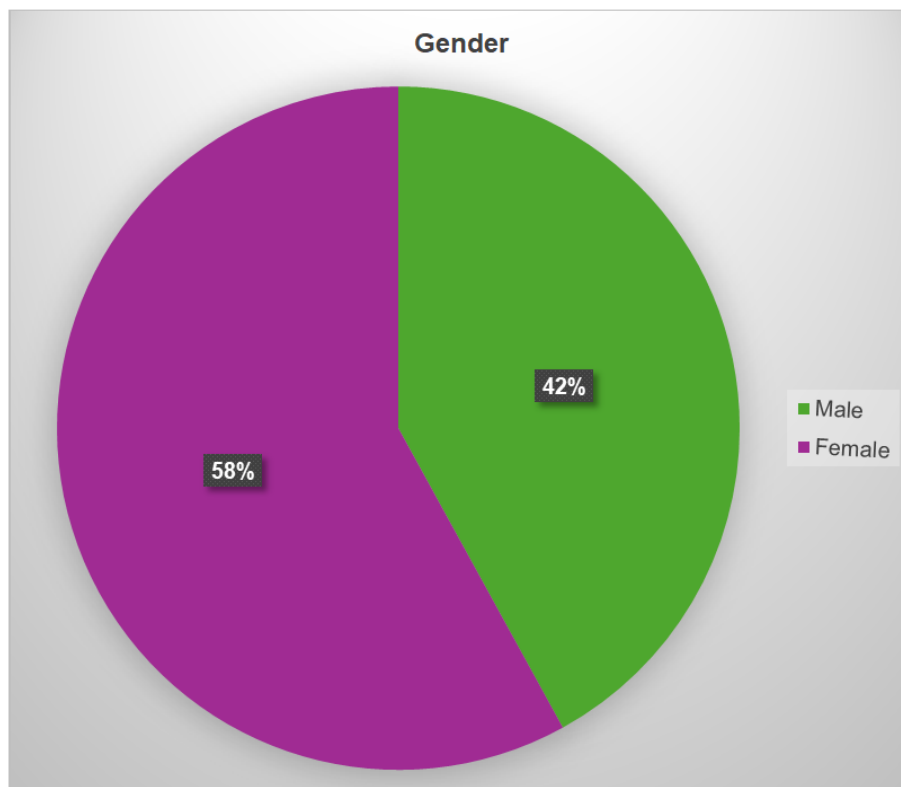


Figure-5: Shows male to female ratio

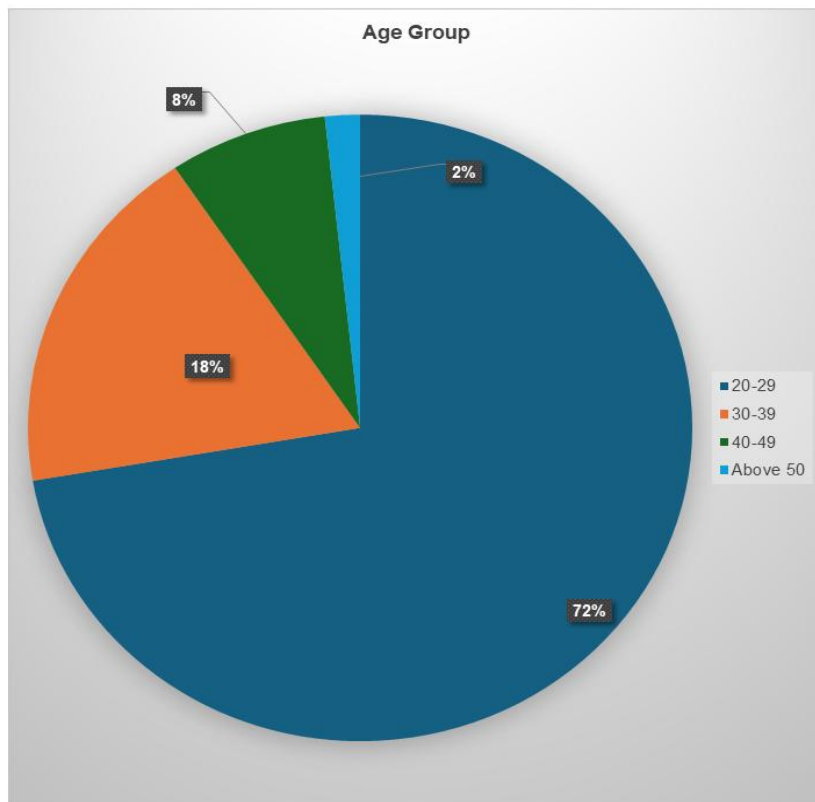


Figure-6: The age range from 20 years old until 63 years old with mean age of 28.19 and standard deviation of 7.347

From 300 OPG, 473 impacted teeth were identified, and as shown in the bar graph Figure(3), the highest percentage was superimposed with 47.3%, followed by

close contact (35.7%), and only 21.7% of the teeth examined has distance between the tooth and the upper border of mandibular canal.

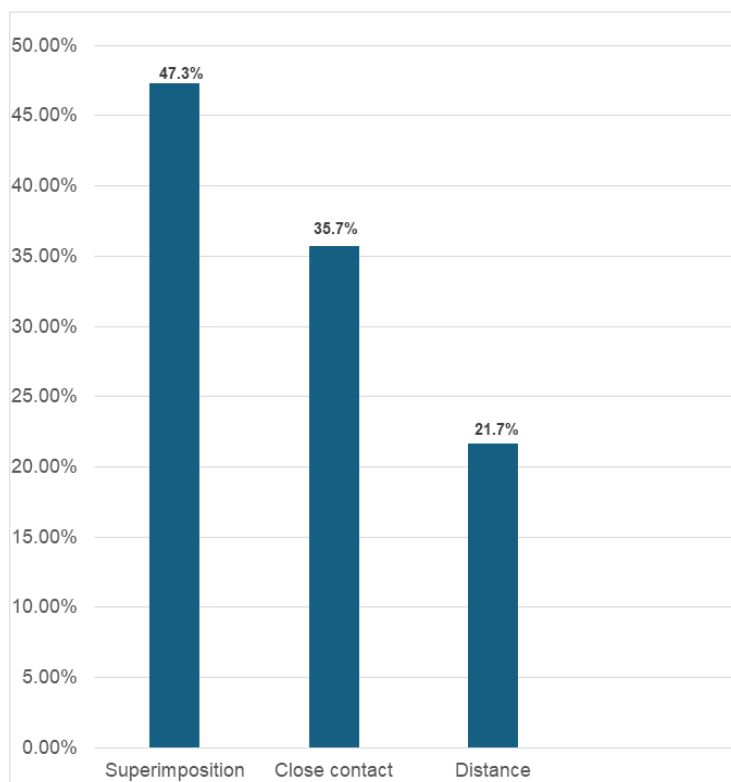


Figure-7: Shows the relationship to the canal

Table-1: The mean measurement of tooth with distance was as follows

	Mean
Mesial (Right)	2.362
Distal (Right)	2.477
Mesial (Left)	2.922
Distal(Left)	3.222

Table-2: Mean distance for gender and age group

		Right		Left	
		Mesial	Distal	Mesial	Distal
Gender	Male	2.240	2.745	3.241	3.489
	Female	2.459	2.206	2.534	2.372
Age Group	20-29	2.550	2.372	2.766	2.830
	30-39	0.957	2.450	3.308	3.153
	40-49	3.233	3.833	2.780	3.450
	50 & above	-	-	2.300	6.400

Age group p=0.016
Gender Lt distal p=0.028

Table-3: Mean distance for type of impaction

		Right		Left	
		Mesial	Distal	Mesial	Distal
Type of impaction	Horizontal	1.589	2.522	2.711	3.974
	Vertical	2.633	2.010	4.150	2.750
	Mesioangular	1.571	2.329	2.412	1.759
	Distoangular	3.271	2.978	2.840	1.911

Rt mesial P=0.006 Lt distal. P=0.000

Table-4: Gender VS Type of Relationship (Right)

		Type of Relation		
		Distance	Close Relation	Superimposition
Gender	Male	23	33	46 36.5%
	Female	28 16.2%	58 33.5%	56 32.4%

P=0.596

Table-5: Gender VS Type of Relationship (Left)

		Type of Relation		
		Distance	Close Relation	Superimposition
Gender	Male	25 19.8%	30 23.8%	42 33.3%
	Female	25 14.5%	46 26.6%	77 44.5%

P=0.673

Table-6:Age Group VS Type of Relationship (Right)

		Distance	Close Relation	Superimposition
		20-29	43 84.4%	71 78%
Age Group	30-39	5 9.8%	14 15.4%	18 17.6%
	40-49	3 5.9%	6 6.6%	7 6.9%
	Above 50	0 0%	0 0%	1 1.0%



Table-7: Age Group VS Type of Relationship (Left)

		Distance	Close Relation	Superimposition
Age Group	20-29	32 64%	57 75%	90 75.6%
	30-39	13 26.0%	13 17.1%	18 15.1%
	40-49	5 10.0%	5 6.6%	8 6.7%
	Above 50	0 0%	1 1.3%	3 2.5%

Table: 8: Type of impaction (RT) VS Type of Relationship

		Type of Relationship		
		Distance	Close Relation	Superimposition
Type of Impaction	Horizontal	12 23.5%	33 36.3%	19 18.6%
	Vertical	9 17.6%	17 18.7%	20 19.6%
	Mesioangular	17 33.3%	23 25.3%	55 53.9%
	Distoangular	13 25.5%	18 19.8%	8 7.8%

P=0.000

Table-9: Type of Impaction (LT) VS Type of Relationship

		Type of Relationship		
		Distance	Close Relation	Superimposition
Type of Impaction	Horizontal	27 54%	22 29.3%	25 21.2%
	Vertical	3 6%	17 22.7%	208 23.7%
	Mesioangular	9 18%	22 29.3%	43 36.4%
	Distoangular	11 22%	14 18.7%	21 17.8%

P=0.000

DISCUSSION

The relationship between the impacted lower third molar and mandibular canal described as distance, contact and superimposition revealed the highest frequency of radiological findings in assessing the relationship between impacted lower third molar and mandibular canal. These three findings do not indicate the presence of perforation of mandibular canal by the impacted lower third molar since this is a 2D radiograph.

The close anatomic relationship between the lower third molar and the mandibular canal may result in inferior alveolar nerve injury during the surgical removal of the lower third molar. The injury will cause paresthesia of the chin and lower lip which affect patient's daily life [4].

Tantanapornkul stated that 32% of OPG with radiographical markers of close contact shows cortical thinning or perforation in CBCT. Thus, this retrospective study of OPG regarding the relationship of IML3dM and mandibular canal is important as a risk factor assessment for the inferior alveolar nerve injury. The most common presentation on the OPG was superimposed with 47.3% and close contact (35.7%). Only 21.7% of the OPGs showed distance between the tooth and the upper border of mandibular canal [5].

With regard to gender, we found out that female group has higher percentage of superimposition with the canal, which indicate higher risk of inferior alveolar nerve injury compared to male. In contrast with our study Blouneau and Renton *et al*. [4,12] they stated in their study that all cases of permanent neurosensory disturbances after removal of lower third molar seen in female patients were more likely to suffer from



permanent nerve injury with male to female ratio of 11:42.

In term of age group, superimposition occurred mostly in age group 20-29 years old in both left and right side of impaction. Kovisto stated that root apices in younger patients (<18 years) were generally closer to the mandibular canal than in older patients [6].

Deshpande *et al.* concluded in his study that panoramic radiographs are reliable in assessing the proximity of IML3dM to MC. In addition to that mesioangular impactions are more closely placed to MC and interruption of the white line is the most reliable risk predictor sign on the panoramic radiographs which comes in convention with our study [10].

In this retrospective study the mesioangular impaction has the highest percentage of superimposition for both right and left side, and it is statistically significant ($p=0.000$). In agreement with our study, Saad *et al* found that mesioangular type of impaction has the highest incidence of close relation and superimposition [11].

Regarding the angulation classifications, mesioangular and vertical impaction has the highest susceptibility to have inferior alveolar nerve injury than other types of impactions [7].

Preparation of the minor oral surgery for IML3dM started with careful examination and diagnosis, initial investigation to do as a routine procedure is OPG by which we can investigate and classify the type of impaction and on the top of that the relationship to the mandibular canal.

This study investigated the impaction patterns and risk factors associated with injury to the inferior alveolar nerve (IAN). However, it had limitations, first the sample size is small as, the findings may not fully reflect the characteristics of the overall. Second, the study included only patients who underwent OPG and not CBCT at the same time, to prove the closed relationship to the canal for comparison. Unlike other studies, this research is a retrospective study focused on OPGs taken for patients with impacted mandibular third molars, as initial investigation. Cases with closed contact with the MC, to be refereed for CBCT for further investigation. As a result, caution is needed when interpreting the findings, and they cannot be generalized to all impacted third molars. As in other studies, it would be essential to differentiate between temporary and permanent nerve injuries and assess the severity of symptoms [8].

The OPG helps the operator determine whether further investigation or surgery is required. If there is a close relation to the canal, a CBCT scan should be performed to provide a 3D image, allowing us to assess the relationship to the mandibular canal more accurately, then operate accordingly [9].

After the initial assessment of the relationship between the impacted mandibular third molar (IML3dM) and the mandibular canal (MC) using OPG, CBCT is effective in providing a 3D view of the third molar and its surrounding structures, specifically MC. CBCT has shown high sensitivity in identifying the exact proximity of the tooth root to the MC. However, it may not necessarily reduce the risk of inferior alveolar nerve injury if the third molar is removed using a conventional approach [13].

There is no association between nerve injury and direct IML3dM contact or canal decorticalization. Although OPG is commonly used to plan for surgical removal of IML3dM, consideration of CBCT as a viable alternative is warranted [14].

CONCLUSION

Higher female to male ratio for superimposition with the mandibular canal, age group of 20-29 has the highest percentage of superimposition, and mesioangular impaction has higher percentage of superimposition. Careful assessment of the OPG can help in determining the relationship between the apices of the IML3dM and the mandibular canal. The importance of this study lies in understanding the relationship to properly conduct CBCT, which helps avoid nerve injuries and reduces the chances of further complications.

Acknowledgment: The authors acknowledge the research project ID: SRCG20-012-0012 for the financial support.

REFERENCES

1. Moore UJ. *Principles of Oral and Maxillofacial Surgery*. Fifth ed. Oxford: Blackwell Publishing, 2001: 112-116.
2. McGowan DA. *An Atlas of Minor Oral Surgery; Principles and Practice*. Second ed. New York: Martin Dunitz Ltd, 1999: 26-49.
3. Malik NA. *Textbook of Oral and Maxillofacial Surgery*. Second ed. New Delhi: Jaypee Brothers, 2008.
4. Renton T, Yilmaz Z. Managing iatrogenic trigeminal nerve injury: a case series and review of the literature. *Int. J. Oral Maxillofac. Surg.*, 2012;41:629-637
5. Tantanapornkul, W., Okouchi, K., Fujiwara, Y., Yamashiro, M., Maruoka, Y., Ohbayashi, N., & Kurabayashi, T. (2007). A comparative study of cone-beam computed tomography and conventional panoramic radiography in assessing the topographic relationship between the mandibular canal and impacted third molars. *Oral Surgery, Oral Medicine, Oral Pathology, Oral Radiology, and Endodontology*, 103(2), 253-259.



6. Kovisto T, Ahmad M, Bowles WR. *Proximity of the mandibular canal to tooth apex*. Journal of Endodontic, 2011 Mar;37(3):311-3.
7. Miloro M. *Principles of Oral and Maxillofacial Surgery*. Second ed Vol 1. Ontario: BC Decker Ic, 2004: 139-155.
8. Kim, H.J.; Jo, Y.J.; Choi, J.S.; Kim, H.J.; Kim, J.; Moon, S.Y. Anatomical Risk Factors of Inferior Alveolar Nerve Injury Association with Surgical Extraction of Mandibular Third Molar in Korean Population. Appl. Sci. 2021, 11, 816. <https://doi.org/10.3390/app11020816>
9. Issrani, R.; Prabhu, N.; Sghaireen, M.; Alshubrmi, H.R.; Alanazi, A.M.; Alkhalaf, Z.A.; Alnusayri, M.O.; Aljohani, F.M.; Khan, Z.A. Comparison of Digital OPG and CBCT in Assessment of Risk Factors Associated with Inferior Nerve Injury during Mandibular Third Molar Surgery. *Diagnostics* 2021, 11, 2282. <https://doi.org/10.3390/diagnostics11122282>.
10. Deshpande P, V Guledgud M, Patil K. Proximity of impacted mandibular third molars to the inferior alveolar canal and its radiographic predictors: a panoramic radiographic study. J Maxillofac Oral Surg. 2013 Jun;12(2):145-51. doi: 10.1007/s12663-012-0409-z. Epub 2012 Aug 26. PMID: 24431832; PMCID: PMC3681992.
11. Saad SS, Al-Saffar AB, Minwah BS. *Relation of the mandibular canal to the root apices of different types of impacted lower 3rd molar*. Al-Rafidain Dental Journal, 2012; 12(1);109-114.
12. Blondeau F, Daniel NG. Extraction of impacted mandibular third molars: postoperative complications and their risk factors. J Can Dent Assoc. 2007 May;73(4):325. PMID: 17484797.
13. Leung YY, Hung KF, Li DTS, Yeung AWK. Application of Cone Beam Computed Tomography in Risk Assessment of Lower Third Molar Surgery. *Diagnostics* (Basel). 2023 Mar 1;13(5):919. doi: 10.3390/diagnostics13050919. PMID: 36900063; PMCID: PMC10001295.
14. Bozkurt P., C. Görürgöz, Detecting direct inferior alveolar nerve – Third molar contact and canal decorticalization by cone-beam computed tomography to predict postoperative sensory impairment, Journal of Stomatology, Oral and Maxillofacial Surgery, Volume 121, Issue 3,2020, Pages 259-263,ISSN 2468-7855,<https://doi.org/10.1016/j.jormas.2019.07.004>.

