

Case Report

DOI: 10.62046/gijams.2024.v02i02.004

Surgical Approach to Pulmonary Cystic Adenomatoid Malformations: About an Observation

Meskouri Karim*, A. Cherbal¹, A. Khelili¹, N. Mebarki¹

¹Assistant in the Thoracic and Cardiovascular Surgery and Organ Transplantation Department at MUSTAPHA University Hospital Alger, ALGERIA

²Professor head of department of Thoracic and Cardiovascular Surgery and Organ Transplantation MUSTAPHA University Hospital Alger, ALGERIA

*Corresponding Author: Meskouri Karim

| Received: 09.01.2024 | Accepted: 02.03.2024 | Published: 11.04.2024

Abstract: Congenital cystic adenomatoid malformation (MAKC) is a congenital anomaly of lung development, and is defined as an adenomatoid proliferation of terminal respiratory structures, bronchial and distal pulmonary cystic dilatation, communicating with the bronchial tree and lacking cartilaginous rings, representing approximately 25% of congenital lung lesions, and in 80 to 85% of cases, the diagnosis is made before the age of 2 and is rarely discovered in adulthood. We report 01 case of MAKC diagnosed at the age of 06 months. The diagnosis was based on clinical elements (episode of bronchiolitis with serious signs at the age of 5 months) and radiological (TLT and CT). The lesion was located in the lower lobe of the right lung. The patient underwent a surgical resection such as a lower right lobectomy removing the lesion in one piece. The discovery of a MAKC must be recognized by clinicians. The clinical diagnosis, strongly oriented by the radiological approach, is confirmed by the anatomical pathology, the therapeutic sanction is surgical in the majority of cases. Most authors indicate surgery, especially in early childhood in order to avoid complications, mainly recurrent infections and pneumothorax, and to take advantage of the potential for lung growth.

Keywords: Congenital Cystic Adenomatoid Malformation, Congenital Developmental Anomaly, Lung, Infectious Complications, Surgery

Citation: K. Meskouri *et al.* Surgical Approach to Pulmonary Cystic Adenomatoid Malformations: About an Observation. Grn Int J Apl Med Sci, 2024 Mar-Apr 2(2): 47-52.

INTRODUCTION

Pulmonary congenital cystic adenomatoid malformation (MAKC) is rare, corresponding to a distal bronchial and pulmonary cystic dilatation, communicating with the bronchial tree and devoid of cartilaginous rings [1]. Stocker established a classification of MAKC, based on the the anatomopathological aspect and mainly on the size of the cysts, distinguishing types I, II and III [1].

It is most often diagnosed in the perinatal period but can be detected, in certain cases, during early childhood. We report a case of MAKC in an NRS, diagnosed following recurrent infectious pneumonia treated and operated on in our department.

CASE PRESENTATION

This is a 6-month-old male infant, with no surgical medical history, admitted to our level for treatment of a cystic adenomatoid malformation of the lower lobe of the right lung.

History: Medical: * Familial: - Healthy non-consanguineous parents

- First child of the couple

*Personal:- premature birth of 36 weeks + 04 days, birth weight 250 grams

Surgical: (No history)

HDM

The Patient presented an episode of bronchiolitis with serious signs at the age of 05 months, where a Telethorax was done revealing a cystic image occupying the lower 2/3 of the right lung, followed by a CT scan.

Telethorax from the Front

Image of multiple rounded cysts limited by fine borders at the level of the lower right lobe, repression of the mediastinum towards the contralateral side and lowering of the left diaphragmatic dome (fig. 1)

THORACIC CT

Appearance suggests cystic adenomatoid dysplasia of the lower lobe of the right lung by multiple contiguous thin-walled cystic formations with homogeneous content whose size varies between 05 mm and 24 mm. (fig2).

General Examination

On admission: Conscious patient, good general condition, good hemodynamic constants, afebrile, polypneic at 64 cycles/min with suprasternal and intercostal drawing.

Asymmetrical thorax with slight hypertrophy of the right hemithorax with reduction in thoracic expansion on the right (fig 3).

Auscultation decrease in gallbladder murmur at the base of the right hemifield.

SUPPORTED

The NRS hospitalized and operated on in our department, approached by a thoracotomy in the 6th intercostal space where the exploration found a giant compressive cystic formation at the expense of the lower lobe of the right lung (occupying 2/3 of the lobe), the rest of the pulmonary parenchyma was healthy (fig. 4)

A lower right lobectomy is performed, removing the malformation in a single block (fig 5).

Operating specimen sent for anatomopathological study (fig 6).

RESULTS

The postoperative course was simple.

- Afebrile and eupneic patient, clean dressing during hospitalization.
- Removal of the chest tube on day 4 of hospitalization, after control telethorax showing good right lung expansion without residual effusion (fig7)
- Patient declared discharged on postoperative day 5
- Favorable evolution with a follow-up of 18 months.

Anapath Results

Lower right lobe contains a cystic formation measuring (8*2*6) cm with a whitish, multilocular cystic appearance on section.

Microscopic examination shows the appearance of an intercommunicating cystic cavity lined with a simple cubic epithelium centered on a cartilaginous lobule with a focus of a PNN microabscess.

Morphological appearance compatible with a hamartomatous lesion of the lung.

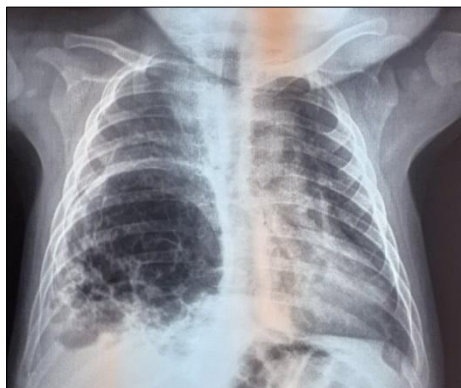

Fig. 1: Téléthorax de face

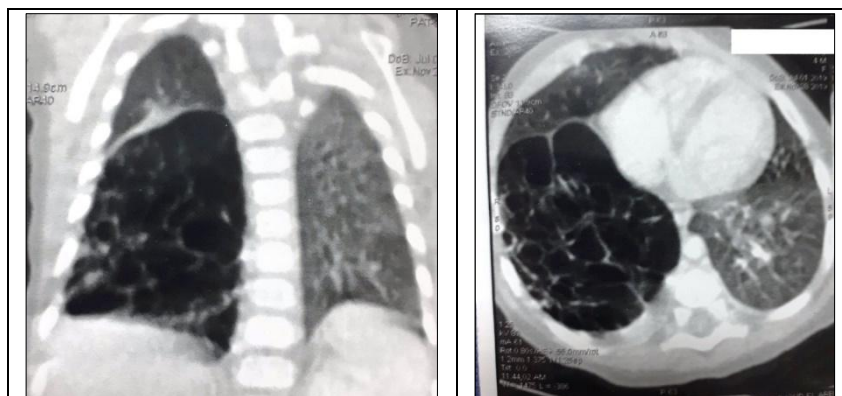


Fig. 2: Thoracic CT (right lower lobar MAKP)

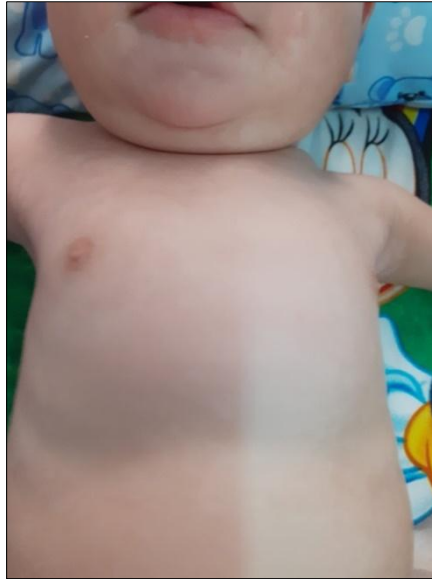


Fig. 3: Deformation of the right hemithorax

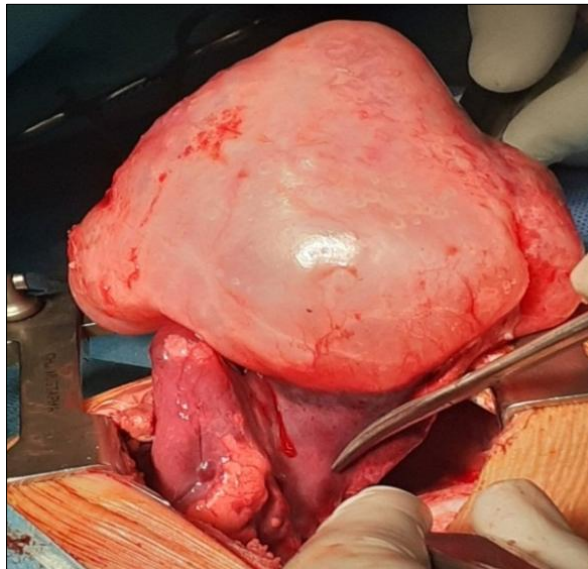


Fig. 4: Intraoperative appearance of the malformation in the lobe.

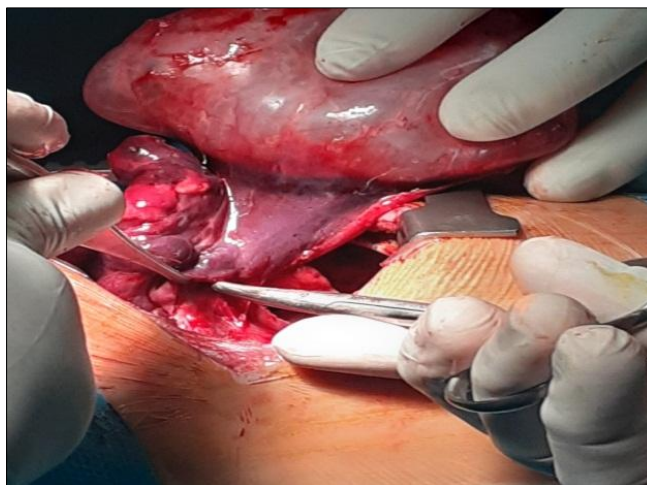

Fig. 5: Lobectomy removing the malformation

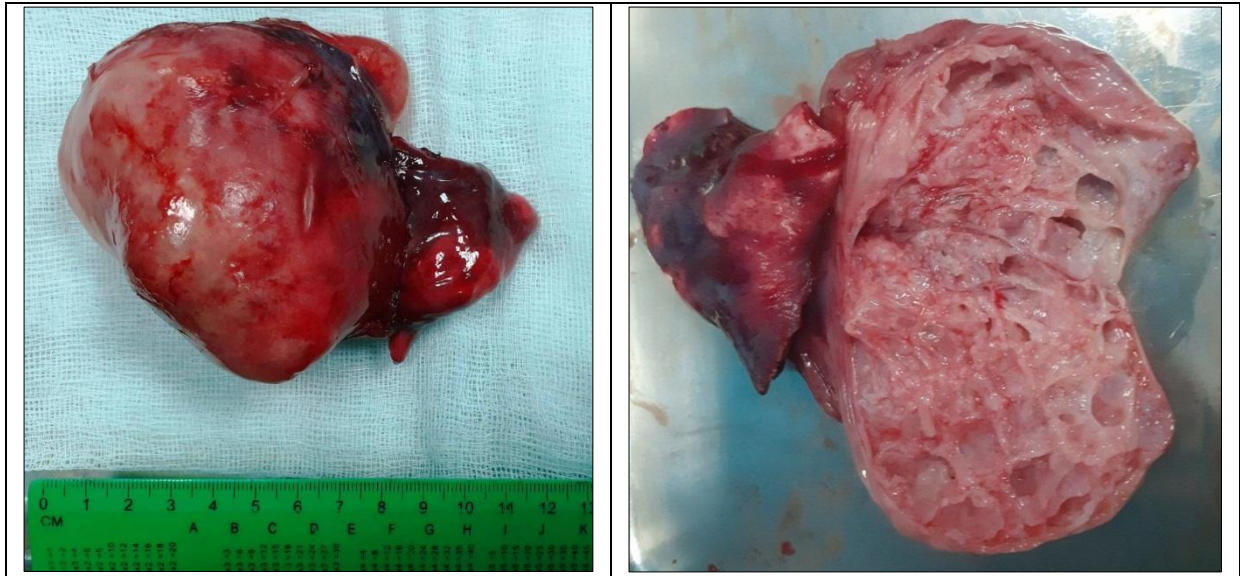


Fig 6: Operating piece

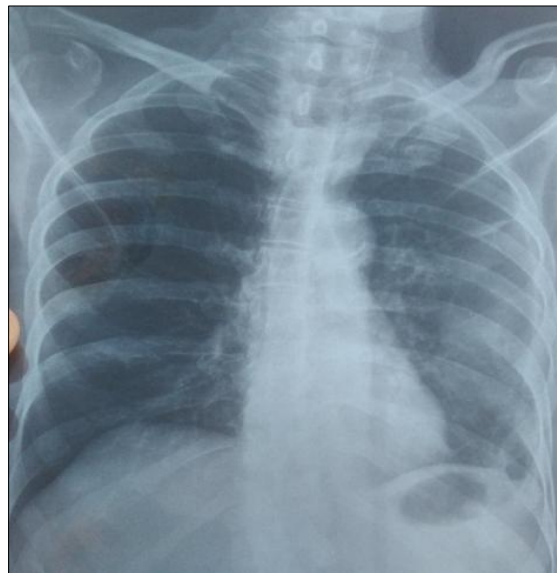


Fig. 7: Control face telethorax on postoperative day 4.

DISCUSSION

MAKC is a rare pulmonary hamartomatous lesion, resulting from an arrest of maturation of the conduction pathways at the level of the bronchioles without the formation of alveolar tissue [3].

It was described by Ch'in and Tang in 1949, and is defined as an adenomatoid proliferation of terminal respiratory structures, manifested by cysts lined by a cylindrical or cubic epithelium [2]. It is identified as a sporadic non-hereditary lesion or can be associated with genetic syndromes such as trisomy 18 or hereditary renal dysplasia [3].

MAKC is uncommon, accounting for 25% of congenital lung lesions.

It is currently reported more and more frequently in the literature thanks to the performance of

ultrasound imaging and its systematization in routine prenatal monitoring [4].

Almost all MAKC are diagnosed during the first two years of life. In 80 to 95% of cases, MAKC only affects one lobe, with a certain tropism for the right lung [2].

The prenatal course of MAKC is variable: it can lead to fetal hydrops in 40% of cases or completely regress in 15% of cases [6].

The mode of revelation may be acute neonatal respiratory distress. It can also be diagnosed in children or even adults due to non-productive cough and recurrent pulmonary infections in the same area, with ultimately the formation of abscessed masses due to insufficient alveolar drainage [7, 8]. Other signs have

been observed such as dyspnea or even cyanosis due to compression, hemoptysis, pneumothorax, pyo-pneumothorax or even arrhythmia [2].

In rare cases, it may remain asymptomatic and be discovered incidentally by radiology. The radiological differential diagnosis is that of circumscribed hyperlucency: diaphragmatic hernia, giant lobar emphysema, bronchogenic or dysembryonic cyst, post-traumatic or infectious pneumatocele. In adults, a lung abscess, a cystic mesenchymal hamartoma or cystic fibrosis can also be suspected [8].

In our patient, sequestration and bronchial dilatation lesions were suspected. CT data correlated well with histological lesions. Chest CT scan reveals multiple air cysts connected to the bronchi and well demarcated from normal lung parenchyma [9].

CT angiography is useful in the differential diagnosis, allowing the search for systemic vascularization which would suggest pulmonary sequestration [10]. Magnetic resonance imaging is of little use in this pathology.

Only the histological study confirms the diagnosis and eliminates other cystic pulmonary malformations. It shows cysts with air or fluid content, limited by a wall devoid of cartilage and without signs of inflammation, lined by an epithelium made up of ciliated pseudo-stratified cells and mucus cells [1]. Kwitken and Reiner described fundamental histological criteria: a cystic adenomatoid proliferation of the terminal bronchioles, a polypoid cystic mucosa rich in elastic fibers, without cartilaginous elements or inflammatory signs, and the occasional presence of alveoli with a mucinous coating [3].

The pathogenesis of MAKC remains unclear. For some, it would be an arrest of bronchial bud development during the embryonic phase induced by a vascularization anomaly or a causal agent (infectious, chemical or other teratogenic) [2-11].

This results in the formation of cysts which can communicate with each other. Stocker *et al.*, [1] described three main types for which they imagined that they could occur at 3 different embryonic periods. This classification is based on macroscopic aspects, histological criteria and the presence or absence of associated congenital malformations [11], [12]:

TYPE I: Observed in 65% of cases, contains one or more large cysts with a diameter greater than 2 cm. This would be a late attack on embryogenesis (due to an anomaly between the 5th and 7th week of gestation).

Type II: (25% of cases), whose anomaly is more distal, is made up of multiple cysts of 0.5 to 2 cm bordered by

a ciliated cubic or cylindrical epithelium without mucus cells.

Type III

(10% of cases), contains innumerable small cysts of less than 0.5 cm corresponding to bronchiolar structures without any alveolar differentiation, giving a pseudo-solid appearance to the lesion, extended to the entire segment or lobe. Pulmonary and compressing the adjacent pulmonary parenchyma.

In general, MAKCs are isolated. However, they are associated with other malformations in 18% of cases, either bronchopulmonary (pulmonary sequestration, tracheal bronchus, pulmonary hypoplasia), or digestive (diaphragmatic hernia), or renal (polycystosis, dysgenesis), or other [3-12].

Treatment varies depending on the time of diagnosis. In the prenatal period, clinical and ultrasound obstetric monitoring is essential. Some authors indicate intrauterine resection or drainage of cysts in cases of MAKC complicated by fetal hydrops.

In the absence of means, therapeutic termination of the pregnancy may be justified in this lethal form. After birth and whatever the age, surgical resection is necessary in symptomatic forms [7].

Lobectomy is preferred

Over segmental resection since it avoids prolonged air leak and recurrent postoperative infections secondary to incomplete resection of the lesion.

In cases of asymptomatic MAKC, the majority of authors indicate surgery especially in early childhood in order to avoid complications, mainly recurrent infections and pneumothorax, and to take advantage of the lung growth potential of the first four years of life [13, 14]. Others recommend abstention because they believe that the progressive risks of MAKC are negligible compared to the morbidity.

CONCLUSION

Here we presented the case of a pulmonary MAKC in a 6-month-old infant who presented with repeated pulmonary infections and then treated and operated in our department with a lower right lobectomy removing the malformation.

This congenital pathology must be recognized by clinicians. The clinical diagnosis strongly oriented by the radiological approach is confirmed by the pathological anatomy, the therapeutic sanction is surgical in the majority of cases.

The majority of authors indicate surgery especially in early childhood in order to avoid complications, mainly recurrent infections and



pneumothorax, and to take advantage of the potential for lung growth.

REFERENCES

1. Stocker, J. T., Madewell, J. E., & Drake, R. M. (1977). Congenital cystic adenomatoid malformation of the lung: classification and morphologic spectrum. *Human pathology*, 8(2), 155-171.
2. Oh, B. J., Lee, J. S., KIM, J. S., LIM, C. M., & Koh, Y. (2006). Congenital cystic adenomatoid malformation of the lung in adults: clinical and CT evaluation of seven patients. *Respirology*, 11(4), 496-501.
3. Stocker, J. T. (1994). Congenital and developmental diseases. In: Dail DH, Hammar SP. Editors. *Pulmonary pathology*. Berlin. Springer-Verlag, 155-81.
4. Belkheiri, M., Elidrissi, F., Bouslamti, T., Eddaniaoui, M., Banani, A., Khabouze, S., Aghoutane, M., Zerhouni, H., Ettayebi, F., Kharbach, A., & Chaoui, A. (2001). Congenital cystic adenomatoid malformation of the lung: antenatal diagnosis in a case. *RevPneumol Clin*, 57, 356-60.
5. Herrero, Y., Pinilla, I., Torres, I., Nistal, M., Pardo, M., & Gómez, N. (2005). Cystic adenomatoid malformation of the lung presenting in adulthood. *The Annals of thoracic surgery*, 79(1), 326-329.
6. Shanmugam, G. (2005). Adult congenital lung disease. *European journal of cardio-thoracic surgery*, 28(3), 483-489.
7. Harada, K., Noguchi, T., Miura, T., Kawano, Y., Kashima, K., & Kawahara, K. (2005). Successful treatment of an adult patient with pulmonary abscess secondary to congenital cystic adenomatoid malformation. *The Japanese Journal of Thoracic and Cardiovascular Surgery*, 53, 580-582.
8. Dahabreh, J., Zisis, C. H., Vassiliou, M., & Arnogiannaki, N. (2000). Congenital cystic adenomatoid malformation in an adult presenting as lung abscess. *European journal of cardio-thoracic surgery*, 18(6), 720-723.
9. Patz Jr, E. F., Müller, N. L., Swensen, S. J., & Dodd, L. G. (1995). Congenital cystic adenomatoid malformation in adults: CT findings. *Journal of computer assisted tomography*, 19(3), 361-364.
10. Vicidomini, G., Santini, M., Baldi, A., Cesarano, T., Di Marino, M. P., & Baldi, F. (1997). Cystic adenomatoid malformation of the lung in an adult. *MinervaChir*, 52, 469-73.
11. Lackner, R. P., Thompson, A. B., Rikkers, L. F., & Galbraith, T. A. (1996). Cystic adenomatoid malformation involving an entire lung in a 22-year-old woman. *The Annals of thoracic surgery*, 61(6), 1827-1829.
12. McLean, S. E., Pfeifer, J. D., Siegel, M. J., Jensen, E. R., Schuler, P. M., Hirsch, R., & Mychaliska, G. B. (2004). Congenital cystic adenomatoid malformation connected to an extralobar pulmonary sequestration in the contralateral chest: common origin?. *Journal of pediatric surgery*, 39(8), e13-e17.
13. Granata, C., Gambini, C., Balducci, T., Toma, P., Michelazzi, A., Conte, M., & Jasonni, V. (1998). Bronchioloalveolar carcinoma arising in congenital cystic adenomatoid malformation in a child: a case report and review on malignancies originating in congenital cystic adenomatoid malformation. *Pediatric pulmonology*, 25(1), 62-66.
14. Stacher, E., Ullmann, R., Halbwedl, I., Gogg-Kammerer, M., Boccon-Gibod, L., Nicholson, A. G., ... & Popper, H. H. (2004). Atypical goblet cell hyperplasia in congenital cystic adenomatoid malformation as a possible preneoplasia for pulmonary adenocarcinoma in childhood: a genetic analysis. *Human pathology*, 35(5), 565-570.

