

## Research Article

DOI: 10.62046/gijams.2024.v02.i05.006

### Salivary Gland Tumours in Children and Adolescents-A Study in Shaheed Monsur Ali Medical College & Hospital, Uttara, Dhaka, Bangladesh

Dr. Atiur Rahman<sup>1</sup>

Assistant Professor, Dept. of ENT, Shaheed Monsur Ali Medical College & Hospital, Uttara, Dhaka, Bangladesh

\*Corresponding Author: Dr. Atiur Rahman | Received: 15.09.2024 | Accepted: 15.10.2024 | Published: 22.10.2024

**Abstract:** **Introduction:** Salivary gland carcinomas (SGCs) are rare neoplasms in adults, but are exceedingly infrequent in children, with a reported annual incidence of 0.8–1.4 per million populations under 20 years old. Like other pediatric very rare tumors, SGCs in children and adolescents often present diagnostic and therapeutic challenges for pathologists, surgeons, and pediatric oncologists. **Objective:** To assess the salivary gland tumours in children and adolescents. **Methods:** A cross-sectional observational study was carried out at Dept. of ENT, Shaheed Monsur Ali Medical College & Hospital, Uttara, Dhaka, Bangladesh from January to June 2023. Total 60 patients included in our study. Our pre-operative clinical diagnoses were based on size, shape, mobility, fixity of the tumour to the underlying structures, ulceration of overlying skin, involvement of facial nerve by its malignant transformation and fine needle aspiration cytology. All patients, or their guardians, gave their informed consent for data collection within the national rare tumour group and analysis. **Results:** Total sixty (60) cases of salivary gland tumours were available for our study. Out of 55% were male and 45% were female patients. Incidence of tumours is highest in the age group of 41-50 with 13 cases (21.6% of the total). The least affected age group was the 0-10 group with only one patient (3.3%). Women accounted for 16 cases of the total 33 benign neoplasias (55% of the total). Of the 33 benign tumour, 18 were in males (54.5% of all benign tumours) and 15 were in females (45.5%). Total 60 operated cases). Of these, 32 were pleomorphic adenomas (53.3%) and 1 was an adenolymphoma (1.6%). the total number of malignant tumours confirmed by HPE were 27 (45%). Of these, most numerous was adenoid cystic carcinoma in 8 cases (13.3%). squamous cell carcinoma and muco epidermoid carcinoma were found in 6 cases each (10%). There were 4 and 3 cases of adenocarcinoma (6.6%) and acinic cell carcinoma (5%) respectively. The parotid glands were also the sole location for the 3 acinic cell carcinomas. No tumours were found in the sublingual gland. The majority of the tumours found in the parotid gland were benign tumours, mainly pleomorphic adenomas with 24 cases (75% of the total parotid tumours). **Conclusions:** The tumours were equally distributed between males and females. The tumours were most commonly found in the third to fifth decades of life. The most common benign tumour and the most common tumour overall was pleomorphic adenoma making up 54.5% of all tumours. Surgical excision was the most commonly done treatment. The most commonly done surgical procedure was superficial parotidectomy.

**Keywords:** lower third molar, mandibular canal, impacted, orthopantomogram, retrospective.

**Citation:** Atiur Rahman. Salivary Gland Tumours in Children and Adolescents-A Study in Shaheed Monsur Ali Medical College & Hospital, Uttara, Dhaka, Bangladesh. Grn Int J Apl Med Sci, 2024 Sep-Oct 2(5): 211-218.

## INTRODUCTION

Salivary gland carcinomas (SGCs) are rare neoplasms in adults but very rare in children. The annual incidence is 0.8–1.4 per 1 million inhabitants under the age of 20 [1]. Their incidence in the pediatric population does not exceed 0.8 per 1,000,000 [2], accounting for less than 10% of all head and neck cancers in children [3]. As with other very rare tumors in children, SGCs in children and adolescents often pose diagnostic and therapeutic challenges for pathologists, surgeons, and pediatric oncologists. In the absence of specific standardized pediatric guidelines, treatment is often determined on a case-by-case basis based on guidelines

validated for adult patients. However, some differences have been reported between children and adults regarding the histological spectrum and clinical behavior of SGCs [4]. When treating cancers in children and adolescents, special consideration should also be given to possible long-term effects [5]. What SGC has in common with other very rare pediatric tumors (VRTs) is not only its low incidence but also that it has always been an “orphan” disease, i.e. few clinical and biological details are available and specific protocols to help pediatric oncologists and surgeons define the best treatment have not been developed for a long time. Pediatric SGC is often diagnosed in the

second decade of life (median age 15 years) [6, 7]. It is very rare under 10 years of age, but it is more likely to be highly malignant and lead to a poor prognosis [8]. Although cases of familial aggregation of SGC have been reported, no genetic predisposition syndromes have been reported, and the etiology of SGC may be related to multiple susceptibility genes and/or environmental factors [9-11]. A personal history of cancer and its treatment are considered to be potential risk factors for the development of SGC [12]. However, a clear association with increased risk could only be demonstrated for previous radiation exposure [13-15]. Atypical distribution of tumor sites has been noted in some of the above studies. The high proportion of palatal tumors in B. minor glands suggests selection bias [13], while other cohorts included young adults and patients with benign tumors such as pleomorphic adenoma [16]. In addition, concerns regarding treatment-related late effects (especially those related to radiation therapy in survivors) may affect the treatment approach in different age groups. The differential diagnosis of parotid tumors includes benign adenomas (e.g., pleomorphic adenoma) and metastases of other cancers such as lymphoma, sarcoma, and neuroblastoma. In contrast to adults, salivary gland tumors in children are more often malignant (10–25% vs. 50%), and therefore a possible or probably malignant diagnosis should be considered for noninflammatory salivary gland masses to avoid diagnostic and therapeutic abuse [17,18].

**MATERIALS & METHODS**

**Methods:** A cross-sectional observational study was carried out at Dept. of ENT, Shaheed Monsur Ali Medical College & Hospital, Uttara, Dhaka, Bangladesh from January to June 2023. Total 60 patients included in our study. Our pre-operative clinical diagnoses were based on size, shape, mobility, fixity of the tumour to the underlying structures, ulceration of overlying skin, involvement of facial nerve by its malignant transformation and fine needle aspiration cytology. All patients, or their guardians, gave their informed consent for data collection within the national rare tumour group and analysis. Histological diagnoses were made by local pathologists

and centrally reviewed by national reference committees. Histological diagnoses (histological type and grade) were classified according to the 2005 World Health Organization (WHO) Classification of Tumors of the Head and Neck and the 2008 Armed Forces Institute of Pathology (AFIP) Atlas of Tumor Pathology - Tumors of the Salivary Glands. Disease stage was determined according to the Union for International Cancer Control (UICC) Tumor-Node-Metastasis (TNM) staging system (8th edition).

In the absence of specific pediatric guidelines, treatment was based on the recommendations of national VRT groups, which were not yet uniform during the period described here. In addition, some patients were treated based on the decisions of their local tumor boards, and contact with national bodies was only made after surgery. After preoperative evaluation, extensive tumor removal with sialadenotomy was recommended. In cases of primary parotid gland involvement, partial or total parotidectomy (depending on tumor size and anatomical extent) with the aim of achieving free margins was the mainstay of treatment. Referral to a surgical center with an experienced pediatric surgeon or ENT surgeon specializing in the treatment of SGC was strongly recommended. Tumor resection with simultaneous facial nerve monitoring was recommended.

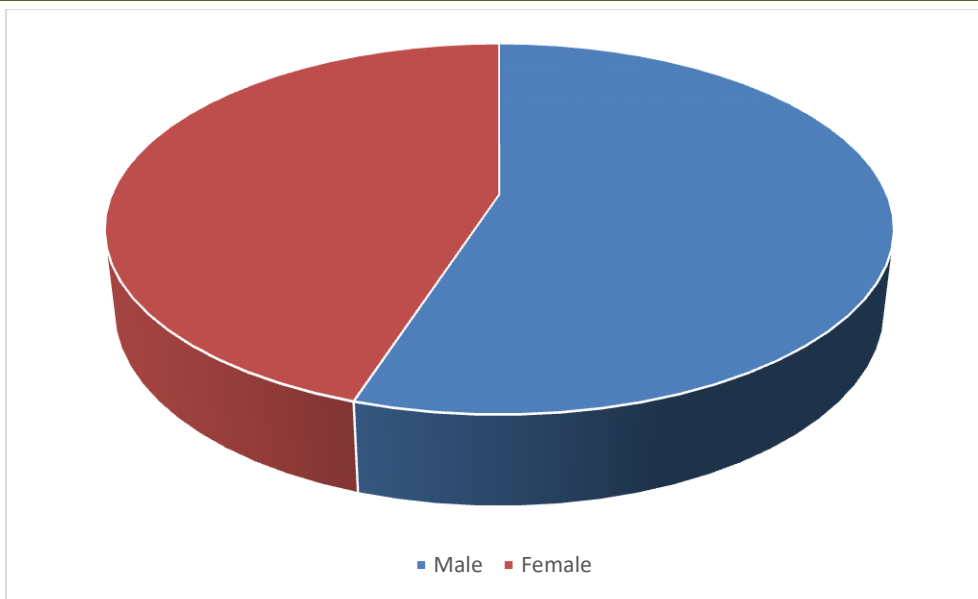
**RESULTS**

Total sixty (60) cases of salivary gland tumours were available for our study. Incidence of tumours is highest in the age group of 41-50 with 13 cases (21.6% of the total). Out of 55% were male and 45% were female patients. The 21-30 and 31-40 age groups are the second most afflicted group with 14 cases (23.3%) each. The least affected age group was the 0-10 group with only one patient (3.3%). The youngest patient was a male child of age 5 years and the oldest was a female patient of age 75 years. The breakup between age groups among males also follows that of the total distribution with majority of cases numbering in the age group 21-30, 31-40 (table-1).

**Table-1: Distribution of the patient’s age**

Age Group in Years	N	%
0-10	2	3.33
11-20	5	8.3
21-30	14	23.3
31-40	14	23.3
41-50	13	21.6
51-60	7	11.6
61-70	2	3.3
71 And above	3	5.0





**Fig-1: Sex distribution of the study patients.**

**Table-2: Showing the Age Distribution of HPE Proven Benign and Malignant Tumours**

Age Group	Benign		Malignant	
	Male	Female	Male	Female
0-10	1	-	1	-
11-20	2	1	1	1
21-30	6	4	2	2
31-40	3	3	5	3
41-50	2	5	4	2
51-60	2	2	2	1
61-70	1	-	-	1
>70	1	-	-	2

Women accounted for 16 cases of the total 33 benign neoplasias (55% of the total). Men had the remaining 18 cases (54.4%). So, the female: male ratio is 1.2:1 in case of benign tumours. Men accounted for 15 out of the total 27 cases of malignant tumours (55.5% of the total). Women made up the rest 12 cases (44.4%) the

men to women ratio are 1.25:1. Overall, most of the benign cases are found in the 21-30 age group. The maximum number of malignant cases was found in the 31-50 age group with 13 cases (48.1% of the total 27 cases) (table-2).

**Table-3: Showing the distribution of HPE confirmed benign and malignant tumours among the sexes**

Sex	Male	Female	Total Tumour Types
Benign	18	15	33
Malignant	15	12	27
Total tumours among sexes	33	27	60

Table-3 shows that, of the 33 benign tumour, 18 were in males (54.5% of all benign tumours). 15 were in females (45.5%). 15 of the 27 cases of malignant tumours were in males (55.5% of all malignancies). 12 cases were found in females (44.4%). Of the 27 cases in females,

there were 15 benign (55.5%) and 12 malignant tumours (44.4%). Of the 33 operated cases in males, there were 18 (54.5%) and 15 malignant tumours (45.4%).

**Table-4: Showing the incidence of individual lesions as confirmed by HPE in the operated cases**

Type	Total No. Of Cases	No. Of Individual Cases - % Of Total 60 Operated Cases	Percentage (%) Of The 60 Operated Cases
Benign	33	Pleomorphic Adenoma –32-53.3	55.0
		Adenolymphoma –1-1.7	
Malignant	27	Adenoid Cystic Carcinoma –8-13.3	45.0
		Squamous Cell Carcinoma –6-10.0	
		Muco-Epidermoid Carcinoma –6-10.0	
		Adenocarcinoma –4-6.6	
		Acinic Cell Carcinoma –3-5.0	

Of the 60 operated cases, HPE confirmed 33 cases as benign (55% of the total 60 operated cases). Of these, 32 were pleomorphic adenomas (53.3%) and 1 was an adenolymphoma (1.6%). The total number of malignant tumours confirmed by HPE were 27 (45%). of these,

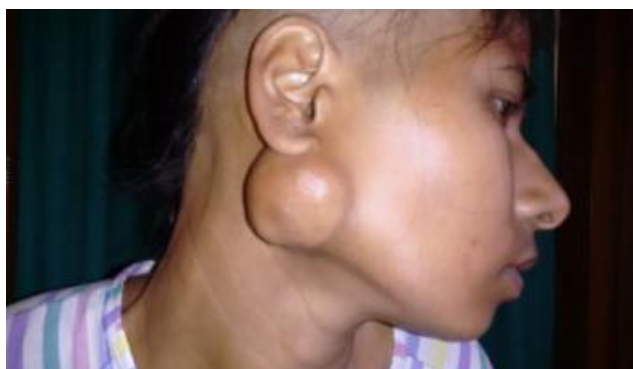most numerous was adenoid cystic carcinoma in 8 cases (13.3%). Squamous cell carcinoma and muco epidermoid carcinoma were found in 6 cases each (10%). There were 4 and 3 cases of adenocarcinoma (6.6%) and acinic cell carcinoma (5%) respectively.

**Table-5: Showing the distribution of the HPE confirmed tumours depending on their site**

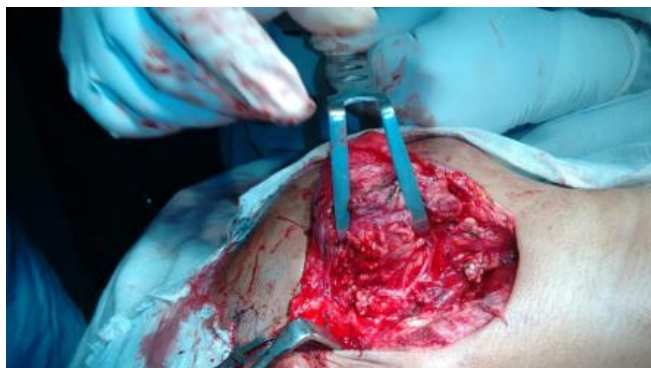Histopathology	Parotid	Submandibular Gland	Sublingual Gland	Minor Salivary Gland	Total
Pleomorphic Adenoma	24	7	-	1	32
Adenolymphoma	1	-	-	-	1
Adenocystic Carcinoma	3	-	-	5	8
Squamous Cell Carcinoma	5	1	-	-	6
Muco-Epiderrmoid Carcinoma	6	-	-	-	6
Adenocarcinoma	1	3	-	-	4
Acinic Cell Carcinoma	3	-	-	-	3
Total	34	9	-	5	60

Of the 32 cases of benign pleomorphic adenoma, 24 were in the parotid gland, 7 in the submandibular gland and 1 in the minor salivary gland. The only adenolymphoma was in the parotid gland. The minor salivary glands were the site for 5 cases of adenoid cystic carcinoma while the parotid gland made up the other 3 cases. Of the 4 cases of squamous cell carcinoma, 5 were in the parotid gland and 1 was in the

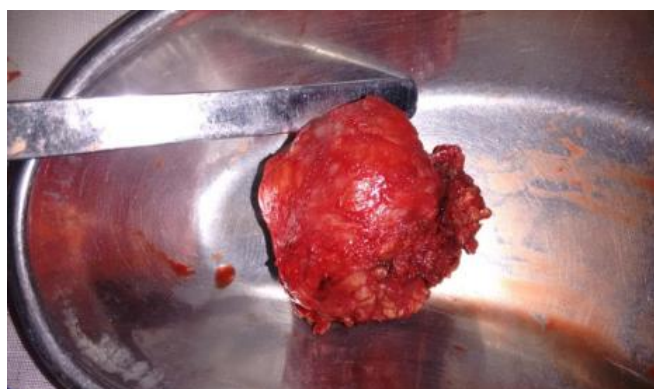submandibular salivary gland. The 6 cases of muco-epidermoid carcinoma were found exclusively in the parotid gland. The parotid glands were also the sole location for the 3 acinic cell carcinomas. No tumours were found in the sublingual gland. The majority of the tumours found in the parotid gland were benign tumours, mainly pleomorphic adenomas with 24 cases (75% of the total parotid tumours).



**Pic-1: Parotid Pleomorphic Adenoma**



**Pic-2: Intra-Operative Picture of Parotid Pleomorphic Adenoma**



**Pic-3: Specimen Picture of Parotid Pleomorphic Adenoma**

## DISCUSSION

Salivary gland cancer (SGC) is rare in children and adolescents. Therefore, there are no standardized recommendations for the diagnosis and treatment of pediatric SGC, and pediatric oncologists and surgeons usually follow adult guidelines. Inflammation of these glands is called sialadenitis. Salivary gland disease is not common in children. If there is a problem, it is usually due to a bacterial or viral infection. Both types cause painful swelling in the affected gland, which can make eating difficult. Salivary gland carcinoma (SGC) is a rare neoplasm in adults but is very rare in children. The annual incidence is 0.8-1.4 cases per million inhabitants under the age of 20 years [11]. Sialolithiasis or lithiasis is the most common benign disease affecting the salivary glands. Its prevalence is estimated at 1.2%. The overall prognosis of primary SGC in children and adolescents is good. The 10-year overall survival (OS) is more than 90% [19]. However, locoregional recurrence and distant metastases are not uncommon, and survival rates for recurrent patients vary greatly depending on the histological type and grade of the tumor. Poor outcomes after salvage therapy strongly support the need for appropriate initial treatment with an aggressive approach, especially for high-risk tumors. However, overtreatment of low-risk tumors must be avoided because of the potential risk of late side effects. Nevertheless, prognostic stratification of pediatric patients with SGC remains a major challenge due to the rarity of these tumors, the difficulty of accurate histological grading, and the overlap between

histological and intrahistologic subtypes. Sixty cases of salivary gland tumors were available for our study. Incidence of tumours is highest in the age group of 41-50 with 13 cases (21.6% of the total). The 21-30 and 31-40 age groups are the second most afflicted group with 14 cases (23.3%) each. The least affected age group was the 0-10 group with only one patient (3.3%). The youngest patient was a male child of age 5 years and the oldest was a female patient of age 75 years. The breakup between age groups among males also follows that of the total distribution with majority of cases numbering in the age group 21-30, 31-40. A study in Brazil by Solanger (2005) on 493 cases of salivary gland tumours resulted in a female: male ratio of 1.25:1[20]. Another study carried out in Brazil by Felipe et al (2012) on 245 cases obtained a female: male ratio of 1.5:1[21]. Another study done in India by maya et al (2014) on 30 cases of intraoral salivary gland tumours had only ten cases as males making the female: male ratio of 2:1[22]. Women accounted for 16 cases of the total 33 benign neoplasias (55% of the total). Men had the remaining 18 cases (54.4%). So, the female: male ratio is 1.2:1 in case of benign tumours. Men accounted for 15 out of the total 27 cases of malignant tumours (55.5% of the total). Women made up the rest 12 cases (44.4%) the men to women ratio are 1.25:1. Overall, most of the benign cases are found in the 21-30 age group. The maximum number of malignant cases was found in the 31-50 age group with 13 cases (48.1% of the total 27 cases). In the other Brazilian Study by Felipe et al, they found a female preponderance

amongst both benign and malignant cases. The female to male ratio in benign neoplasms was 1.25:1 while in malignancies it was 1.11:1 paralleling our study [23]. In our study benign tumours were not discovered in the first decade of life. This is in keeping with the findings of Solanger et al [24]. Similarly, we did find two cases of malignant neoplasms in the first two decades of life, one of them was however lost for follow-up so it was not histopathologically proven and the other was a case of adenocarcinoma in the parotid gland in a female. This was in contrast to their study. Of the 33 benign tumour, 18 were in males (54.5% of all benign tumours). 15 were in females (45.5%). 15 of the 27 cases of malignant tumours were in males (55.5% of all malignancies). 12 cases were found in females (44.4%). Of the 27 cases in females, there were 15 benign (55.5%) and 12 malignant tumours (44.4%). Of the 33 operated cases in males, there were 18 (54.5%) and 15 malignant tumours (45.4%). This is in keeping with the results reported by most studies as mentioned by Barnes et al [25]. A high incidence of pleomorphic adenoma was found in patients of the fourth and sixth decade was reported by Eneroth (1971) [26]. Studies by Potdar et al [27] and Verma et al., report a male preponderance in their studies. On the contrary, Castro and his associates (1972) reported a high incidence in children and young adults [28]. Of the 60 operated cases, HPE confirmed 33 cases as benign (55% of the total 60 operated cases). of these, 32 were pleomorphic adenomas (53.3%) and 1 was an adenolymphoma (1.6%). the total number of malignant tumours confirmed by HPE were 27 (45%). of these, most numerous was adenoid cystic carcinoma in 8 cases (13.3%). squamous cell carcinoma and muco epidermoid carcinoma were found in 6 cases each (10%). There were 4 and 3 cases of adenocarcinoma (6.6%) and acinic cell carcinoma (5%) respectively. This is in keeping with most studies by workers such as Khan et al, Bradley et al, Terhaard et al and Watkinson et al., which mentions that about 30 percent of salivary malignancies is made up of adenoid cystic carcinomas. Most of these arise in the minor salivary gland, about 60 percent. Between 25 to 33 percent arise in the parotid gland making a very small proportion of the parotid gland neoplasms [29-32]. According to literature, this tumour is the most common malignant tumour of the submandibular salivary gland, however we found no cases of submandibular salivary gland adenoid cystic carcinomas in our study. Furthermore, it should account for approximately 10–12% of all malignant salivary gland tumours, which is much less than our 43.58%. Of the 32 cases of benign pleomorphic adenoma, 24 were in the parotid gland, 7 in the submandibular gland and 1 in the minor salivary gland. The only adenolymphoma was in the parotid gland. The minor salivary glands were the site for 5 cases of adenoid cystic carcinoma while the parotid gland made up the other 3 cases. Of the 4 cases of squamous cell carcinoma, 5 were in the parotid gland and 1 was in the submandibular salivary gland. A single case of the tumour was detected in the submandibular

salivary gland making up 11.11% of all cases of submandibular salivary gland tumours. As quoted in Scott-Brown, squamous cell carcinoma is very unusual representing less than 1.1% of all salivary gland tumours [33]. The findings of our study in contrast to most studies as adenocarcinoma is the second, as quoted by Barnes et al [25] or the third, as earlier quoted by Irving et al [33] most common salivary gland malignancy. Most studies have also found the same incidence of over half of the submandibular salivary gland tumours being pleomorphic adenomas. The most common site for the minor salivary gland tumours in our study was the palate, which is in keeping with most of the results in literature such as those by Waldron et al, Toida et al and Yih et al, that mentions more than 33 percent of intraoral malignant tumours of salivary gland to be located in the palate [34-36]. Most work shows that minor salivary gland tumours are majorly found in females, except in case of adenoid cystic carcinoma which has no sex predilection. In our study too, the single minor salivary gland pleomorphic adenoma was found in a female and the four adenocystic carcinoma was equally divided between the two sexes. Tumours of sublingual glands are extremely rare as reported by Eveson et al and Perez et al [37,38]. We too did not find any sublingual salivary gland tumours in our study.

## CONCLUSIONS

We came to the following conclusions: A total of 50 salivary gland tumors were examined in this study. The tumors were evenly distributed between men and women. The tumors most often appeared between the third and fifth decades of life. Benign tumors were more common than malignant tumors, accounting for 55% of all tumors. Benign tumors most often appeared in the third decade of life, while malignant tumors most often appeared in the fourth and fifth decades of life. The most common benign tumor and the most common tumor overall was pleomorphic adenoma, accounting for 54.5% of all tumors. The most commonly performed treatment was surgical excision. The most commonly performed surgical procedure was superficial parotidectomy.

## REFERENCES

1. Yoshida EJ, García J, Eisele DW, Chen AM. Salivary gland malignancies in children. *Int J Pediatr Otorhinolaryngol.* 2014; 78(2): 174-178.
2. Kattner P, Strobel H, Khoshnevis N, et al. Compare and contrast: pediatric cancer versus adult malignancies. *Cancer Metastasis Rev.* 2019; 38(4): 673-682.
3. Muenscher A, Diegel T, Jaehne M, Ussmüller J, Koops S, Sanchez-Hanke M. Benign and malignant salivary gland diseases in children. A retrospective study of 549 cases from the Salivary Gland Registry, Hamburg. *Auris Nasus Larynx.* 2009; 36(3): 326-331.



4. Sultan I, Rodriguez-Galindo C, Al-Sharabati S, Guzzo M, Casanova M, Ferrari A. Salivary gland carcinomas in children and adolescents: a population-based study, with comparison to adult cases. *Head Neck*. 2011; 33(10): 1476-1481.
5. Shapiro NL, Bhattacharyya N. Clinical characteristics and survival for major salivary gland malignancies in children. *Otolaryngol Head Neck Surg*. 2006; 134(4): 631-634.
6. Gontarz M, Wyszynska-Pawelec G, Zapala J. Primary epithelial salivary gland tumours in children and adolescents. *Int J Oral Maxillofac Surg*. 2018; 47(1): 11-15.
7. Xu B, Aneja A, Ghossein R, Katabi N. Salivary gland epithelial neoplasms in pediatric population: a single-institute experience with a focus on the histologic spectrum and clinical outcome. *Hum Pathol*. 2017; 67: 37-44.
8. Morse E, Fujiwara RJT, Husain Z, Judson B, Mehra S. Pediatric salivary cancer: epidemiology, treatment trends, and association of treatment modality with survival. *Otolaryngol Head Neck Surg*. 2018; 159(3): 553-563.
9. Bradley P, McClelland L, Mehta D. Paediatric salivary gland epithelial neoplasms. *ORL J Otorhinolaryngol Relat Spec*. 2007; 69(3): 137-145.
10. Albeck H, Bentzen J, Ockelmann HH, Nielsen NH, Bretlau P, Hansen HS. Familial clusters of nasopharyngeal carcinoma and salivary gland carcinomas in Greenland natives. *Cancer*. 1993; 72(1): 196-200.
11. Merrick Y, Albeck H, Nielsen NH, Hansen HS. Familial clustering of salivary gland carcinoma in Greenland. *Cancer*. 1986; 57(10): 2097-2102.
12. Aro K, Klockars T, Leivo I, Mäkitie A. Familial predisposition for salivary gland cancer in Finland. *Clin Med Insights Ear Nose Throat*. 2014; 7: 7-11.
13. Delides A, Velegrakis G, Kontogeorgos G, Karagianni E, Nakas D, Helidonis E. Familial bilateral acinic cell carcinoma of the parotid synchronous with pituitary adenoma: case report. *Head Neck*. 2005; 27(9): 825-828.
14. Depowski PL, Setzen G, Chui A, Koltai PJ, Dollar J, Ross JS. Familial occurrence of acinic cell carcinoma of the parotid gland. *Arch Pathol Lab Med*. 1999; 123(11): 1118-1120.
15. Chiaravalli, S.; Guzzo, M.; Bisogno, G.; De Pasquale, M.D.; Migliorati, R.; De Leonardis, F.; Collini, P.; Casanova, M.; Cecchetto, G.; Ferrari, A. Salivary gland carcinomas in children and adolescents: The Italian TREP project experience. *Pediatr. Blood Cancer* 2014, 61, 1961–1968.
16. Laishram, R.S.; Kumar, K.A.; Pukhrabam, G.D.; Laishram, S.; Debnath, K. Patterns of salivary gland tumors in Manipur, India: A 10-year study. *South Asian J. Cancer* 2013, 2, 250–253.
17. Ellies, M.; Laskawi, R. Diseases of the salivary gland in infants and adolescents. *Head Face Med*. 2010, 6, 1.
18. Gontarz, M.; Wyszynska-Pawelec, G.; Zapala, J. Primary epithelial salivary gland tumours in children and adolescents. *Int. J. Maxillofac. Surg*. 2018, 47, 11–15
19. Boukheris H, Stovall M, Gilbert ES, et al. Risk of salivary gland cancer after childhood cancer: a report from the Childhood Cancer Survivor Study. *Int J Radiat Oncol Biol Phys*. 2013; 85(3): 776-783.
20. Riberio KC, Kowalski LP, Saba LM, Camargo B. Epithelial Salivary Gland Neoplasms in Children and Adolescents: A Forty-Four Year Experience. *Med Pediatr Oncol*; 2002;39:594-600
21. Dardick I, Burford-Mason AP, Garlick DS, Carney WP. The Pathobiology of Salivary Gland II. *Virchowsarchiv A Pathol Anat*; 1992;421:105-13
22. Kayembe MK, Kalengayi MM. Salivary Gland Tumours In Congo (Zaire). *Odontologia-Universidade estadual paulista*; 2002;25:19-22
23. Atula T, Grenman R, Laippalka P, Klemi P.J. Fine Needle Aspiration Biopsy In The Diagnosis Of Parotid Gland Lesions: Evaluation Of 438 Biopsies. *Diagnostic Cytopathology*; 1996;15(3):185-90
24. Riberio KC, Kowalski LP, Saba LM, Camargo B. Epithelial Salivary Gland Neoplasms in Children and Adolescents: A Forty-Four Year Experience. *Med Pediatr Oncol*; 2002;39:594-600
25. Khan AJ, Digiovanna MOP, Ross Da et al. Adenoid Cystic Carcinoma: A Retrospective Clinical Review. *I International Journal Of Cancer*; 2001;96:149-58
26. Ethunandan M, Davies B, Pratt CA, Puxeddu R, Brennan PA. Primary Epithelial Submandibular Salivary Gland Tumors – Review of Management in A District Hospital Setting. *Oral Oncol*; 2009;45:173-6
27. S Wu, G Liu, R Chen, Y Guan. Role Of Ultrasound in The Assessment of Benignity and Malignancy of Parotid Masses. *Dentomaxillofac radiol*; 2012;41(2):131-45
28. Wittich GR, Scheible FW, Hajek PC. Ultrasonography Of the Salivary Glands. *Radiologic Clinics of North America*; 1985;23:29-37
29. Eveson JW et al. Tumours of The Minor (Oropharyngeal) Salivary Glands: A



- Demographic Study Of 336 Cases. *J Oral Pathol*; 1985 Jul; 14(6):500-9
30. LEAFSTEDT SW et al. Adenoid Cystic Carcinoma of Major And Minor Salivary Glands. *Amer J Surg*; 1971:122:756
  31. Goode RK, Auclair PL, Ellis GL. Mucoepidermoid Carcinoma of The Major Salivary Glands. *Cancer*; 1998;82:1217-24
  32. Koul R, Dubey A, Butlerj et al. Prognostic Factors Depicting Disease Specific Survival In Parotid-Gland Tumors. *International Journal of Radiation Oncology, Biology, Physics*; 2007;68:714-8
  33. Irving RM, Moffat DA, Hardy DG et al. Somatic NF2 Gene Mutations in Familial and Non-Familial Vestibular Schwannoma. *Human Molecular Genetics*; 1994;3:347-50
  34. Rawson AJ, Howard JM, Royster HP. Tumors of The Salivary Glands. A Clinicopathologic Study Of 160 Cases. *Cancer*; 1950;3:445-8
  35. MACFARLAND J. Three Hundred Mixed Tumours of The Salivary Gland of Which Six Recurred. *Surgery, Gynecology and Obstetrics*; 1936;88:457-68
  36. Benedict EG, Meigs JV. Tumours Of the Parotid Gland. A Study Of 225 Cases with Complete End-Results In 80 Cases. *Surgery, Gynecology and Obstetrics*; 1930;51:626-47
  37. Riberio KB, Kowalski LP, Saba LM, Camargo B. Epithelial Salivary Glands Neoplasms In Children And Adolescent: A Forty-Four-Year Experience. *Medical And Pediatric Oncology*. Jan 2003;39(6):594-600.
  38. Perez DE, Pires FR, Alves F, De A et al. Sublingual Salivary Gland Tumours: A Clinicopathological Study of Six Cases. *Oral Surgery, Oral Medicine and Oral Pathology*; 2005;100:449-53.