

## Case Report

DOI: 10.62046/gijams.2025.v03i03.001

### Pseudo Foster Kennedy Syndrome with Parkinson's disease: A Case Report

Dhanisha JL<sup>1</sup>, Heber Anandan<sup>2</sup>, Preethi Anie E<sup>3</sup>, Jenisha Blessie K<sup>4</sup>

<sup>1</sup>Assoc. Professor & Principal, Dr Agarwal's Institute of Optometry, Tirunelveli, Tamil Nadu, India

<sup>2</sup>Professor & Head of Academics, Dr Agarwal's Institute of Optometry, Tirunelveli, Tamil Nadu, India

<sup>3</sup>Asst.Professor, Dr Agarwal's Institute of Optometry, Tirunelveli, Tamil Nadu, India

<sup>4</sup>Lecturer, Dr Agarwal's Institute of Optometry, Tirunelveli, Tamil Nadu, India

\*Corresponding Author: Heber Anandan | Received: 15.02.2025 | Accepted: 23.04.2025 | Published: 01.05.2025

**Abstract:** This case report describes a 70-year-old male patient who reported experiencing sudden blurred vision in his right eye over the past week. The patient has been managing glaucoma for five years, during which he underwent peripheral iridotomy in both eyes, but he has not been on any anti-glaucoma medications. Furthermore, he has been living with diabetes mellitus for 20 years and is also dealing with Parkinson's disease. After many tests, such as a fundus examination, perimetry, OCT, MRI scan, and fundus photography, it was found that the patient had papilledema in the right eye due to ischemic optic neuropathy and primary optic atrophy in the left eye due to Non-Arteritic Anterior Ischemic Optic Neuropathy (NAION). This led to the diagnosis of pseudo-foster Kennedy syndrome (PFKS).

**Keywords:** Pseudo Foster Kennedy syndrome (PFKS), Glaucoma, Optic atrophy, and papilledema.

**Citation:** Dhanisha JL *et al.* Pseudo Foster Kennedy Syndrome with Parkinson's disease: A Case Report. Grn Int J Apl Med Sci, 2025 May-Jun 3(3): 103-109.

## INTRODUCTION

Foster-Kennedy syndrome is a rare clinical condition characterized by the presence of unilateral optic disc swelling along with contralateral optic nerve atrophy. This syndrome typically arises due to an intracranial mass, such as a tumor, which exerts compression on the optic nerve, leading to these distinctive ocular manifestations [1, 2]. However, when similar findings are observed without an identifiable intracranial mass, the condition is classified as Pseudo-Foster-Kennedy syndrome [4]. Pseudo-Foster-Kennedy syndrome can be attributed to an array of conditions that affect the optic nerve and surrounding structures. Among the most common causes are Non-Arteritic Anterior Ischemic Optic Neuropathy (NAION) and Arteritic Anterior Ischemic Optic Neuropathy (AAION) which represent two distinct pathological processes affecting the blood supply to the optic nerve [5,6]. Other notable causes include pachymeningitis, incidental trauma, optic neuritis, infectious processes such as syphilis, and systemic vascular conditions like subdural hematoma and severe arteriosclerosis of the internal carotid arteries [7-10]. Nutritional deficiencies, particularly vitamin B12 deficiency and low folate levels, as well as metabolic disorders such as hypertension, diabetic mellitus, hyperhomocysteinemia, and diabetic papillopathy also contribute to the development of this syndrome [11,12]. In this report, we present a unique

case of a patient diagnosed with Parkinson's disease and angle closure glaucoma who exhibited manifestations consistent with the pseudo-Foster-Kennedy syndrome. This case highlights the potential for various neurological conditions to produce similar optic nerve findings, emphasizing the need for a thorough clinical evaluation and a differential diagnosis approach when encountering such ocular presentations. We aim to understand the pseudo-Foster-Kennedy syndrome, particularly in neurodegenerative disorders [14] and to underscore the importance of recognizing the interplay between systemic and neurological diseases in ophthalmic presentation.

## CASE SUMMARY

A 70-year-old male patient presented with a sudden onset of blurred vision in his right eye (RE) over 1 week. The patient had a history of glaucoma for 5 years and had undergone peripheral iridotomy in both eyes and had not utilized any anti-glaucoma medication. Additionally, he had a 20-year history of diabetes mellitus (DM) and Parkinson's disease. His uncorrected visual acuity (UCVA) was 6/36 in the right eye and 6/24 in the left eye (LE). In slit lamp examination, the pupil showed a relative afferent pupillary defect in both eyes. Following fundus examination, perimetry, MRI scan, and OCT investigations, the patient received the following diagnoses: 1. age-related nuclear cataract in

both eyes (BE), 2. chronic angle-closure glaucoma in both eyes, 3. primary optic atrophy in the left eye secondary to non-arteritic anterior ischemic optic neuropathy (NAION), and ischemic optic neuropathy (ION) in the right eye secondary to NAION.

### DISCUSSION

The clinical presentation observed in this patient is consistent with Foster-Kennedy syndrome. In Foster-Kennedy Syndrome, one optic nerve is atrophied, and the other optic nerve exhibits disc edema (papilledema) due to an intracranial mass such as a suprasellar mass [3]. In this case, the damage to the optic nerves is caused by chronic angle closure glaucoma and NAION rather than intracranial mass, so the patient has pseudo-foster Kennedy syndrome. Patil *et al.* concluded that “NAION in one eye can cause recurrence in the fellow eye also present as pseudo foster Kennedy syndrome” [4].

The visual field of the patient was assessed in which the Central 24-2 threshold program of each eye was assessed with PI standard. The examination of the GHT reveals outside the normal limit in both eyes. The mean deviation was -22.27DB in the right eye and -30.73 dB in the left eye the pattern deviation was 6.06 dB in the right eye and 4.50 dB in the left eye. These results indicate a reduction in the patient’s macular field of vision due to optic atrophy in the left eye.

The central visual field was assessed using the HFA 10-2 program with the SITA standard. The examination of the GHT revealed results outside the normal limit in both eyes. The mean deviation was -26.71 dB in the left eye and -20.83 dB in the right eye. The pattern deviation was 9.21 dB in the left eye and 7.09 dB in the right eye. These results indicate a reduction in the patient’s macular field of vision due to optic atrophy in the left eye and papilledema in the right eye.

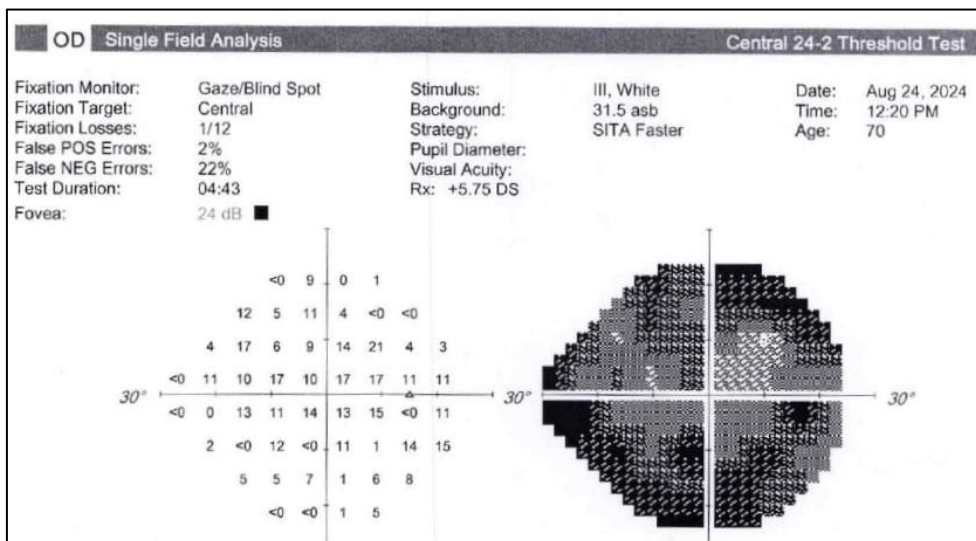
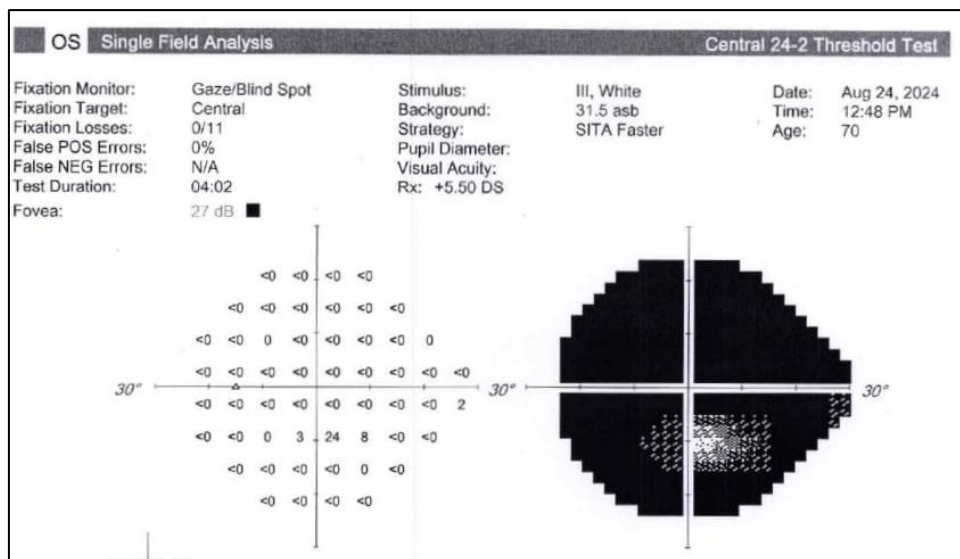


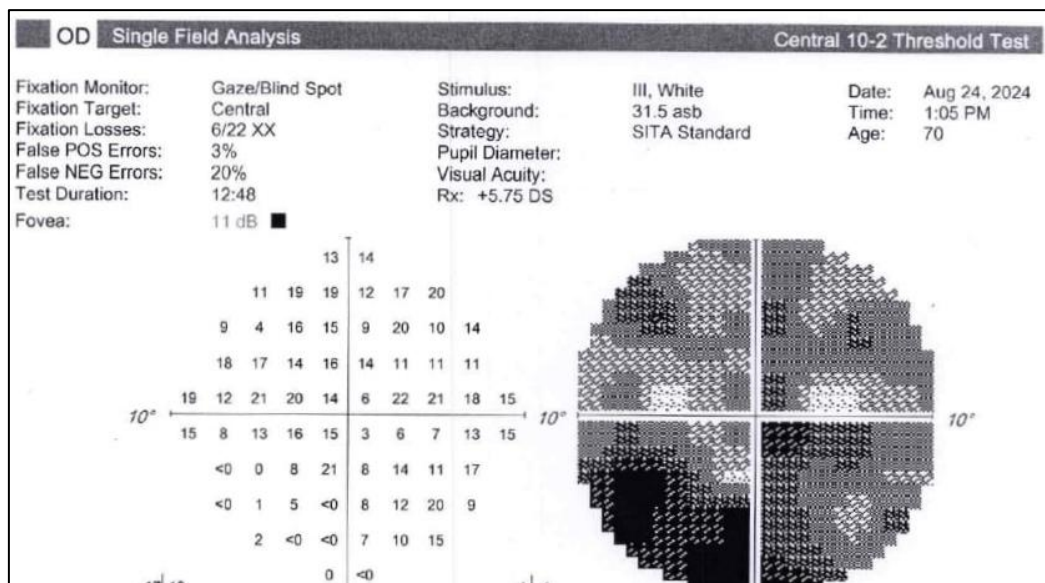
Fig-1: HFA 24-2 OD macular program depicts unreliable visual field loss due to impairment of fixation



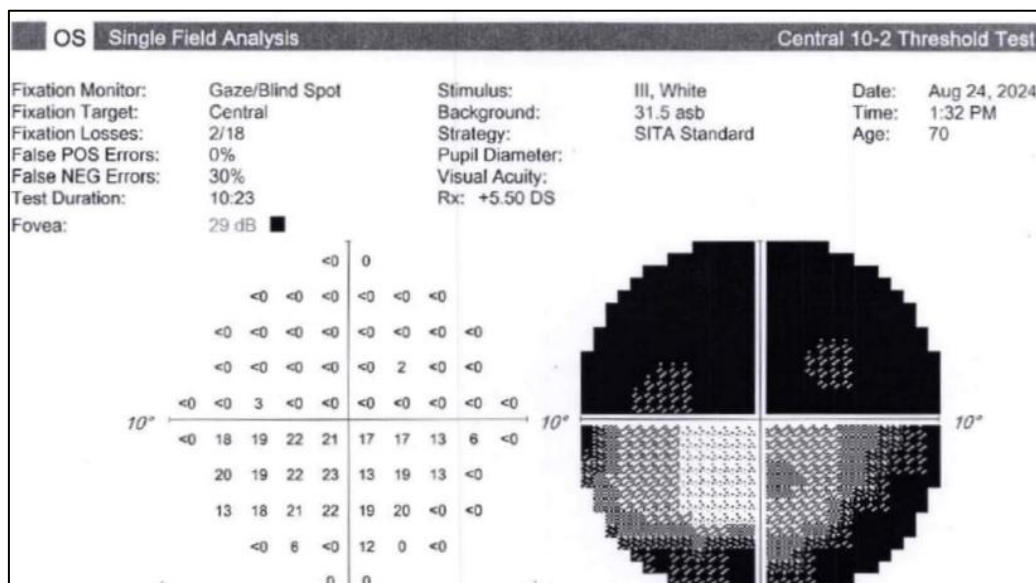
**Fig-2: HFA 24-2 OS macular program depicts unreliable visual field loss due to impairment of fixation**

Visa Rene *et al.*, in their studies, concluded that visual field loss is present in the eye with optic atrophy, and the other eye is normal despite optic disc edema[13].

However, in our case, due to the severity of Parkinson’s disease, the patient was unable to do the visual field assessment, which resulted in unreliability.



**Fig-3: HFA 10-2 -OD depictsunreliable visual field loss due to impairment of fixation**



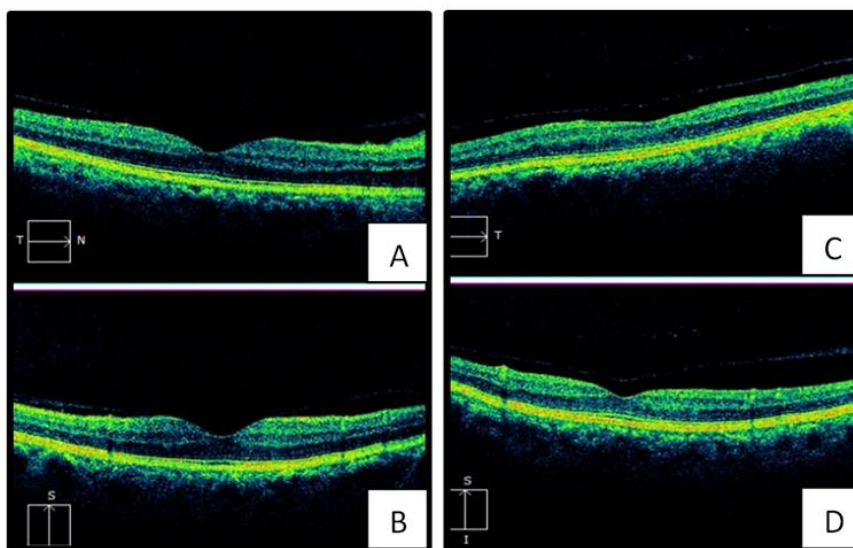
**Fig-4: HFA 10-2 -OS depicts altitudinal field loss**

In addition to that, the patient in our case has Parkinson’s disease. Patients with Parkinson’s disease have the following ophthalmic features, such as ocular surface irritation, altered tear film, visual hallucinations, blepharospasm, decreased blink rate, and decreased convergence amplitudes which were more common in Parkinson’s disease patients [14]. Parkinson’s patients also have retinal disorders such as retinal degeneration, retinal layers thinning, and macula used to have reduced thickness [15,16]

Verghese *et al.* concluded in their case-control study that” macular volume has significant thinning” [17,18]in Parkinson’s disease. Our study also showed that the OCT macula scan of the left eye, the macular thickness analysis program, indicated a normal central subfield thickness of 251  $\mu\text{m}$ , a normal outer temporal quadrant (250  $\mu\text{m}$ ), decreased thickness in the inner temporal quadrant (278  $\mu\text{m}$ ), the inner superior quadrant (289  $\mu\text{m}$ ), the inner nasal quadrant (284  $\mu\text{m}$ ), the inner inferior quadrant (284  $\mu\text{m}$ ), the outer superior quadrant (248  $\mu\text{m}$ ), the outer nasal quadrant (257  $\mu\text{m}$ ), and the outer inferior quadrant (243  $\mu\text{m}$ ).These values

showed thinning in macular thickness in the patient's

left eye.



**Fig-5: OD (A and B): OCT Macula Fig .6: OS (C and D): OCT Macula depicts Papilledema depicts optic atrophy**

OCT macula scan of the right eye, the macular thickness analysis program revealed a normal central subfield thickness of 285µm and normal thickness in the inner temporal quadrant (327µm), inner superior quadrant (341µm), inner nasal quadrant (347µm), inner inferior quadrant (313µm), outer temporal quadrant (266µm), outer superior quadrant (283µm), normal outer inferior quadrant (254µm), and increased outer nasal quadrant (337µm). These values showed the thickening of the outer nasal quadrant of the macula in the right eye.

A comparison of the right and left eye OCT macula scans showed that macular thinning was more pronounced in the left eye, with only the central subfield and outer temporal quadrants exhibiting normal thickness. This suggests reduced macular thickness in the left eye due to NAION. In addition to

that, the patient has Parkinson's disease and increased outer nasal quadrant thickness in the right eye due to ischemic neuropathy [19].

Orbit screening of our studies showed altered hyper-intense signal change involving the left retro bulbar optic nerve near the orbital apex in T2W and STIR images, which are suggestive of acute/subacute left optic neuritis causing optic atrophy in the left eye. Also in the studies of Desai *et al.*, orbital and brain MRI reveals left lateral ventriculomegaly with downward displacement of the gyrus rectus, resulting in left optic nerve compression causing optic atrophy in the left eye showing the absence of intracranial lesions [20]

The B-scan report shows a normal posterior segment in both eyes. Semeraro *et al.*, in their studies, showed normal B-scan reports in PFKS [21].

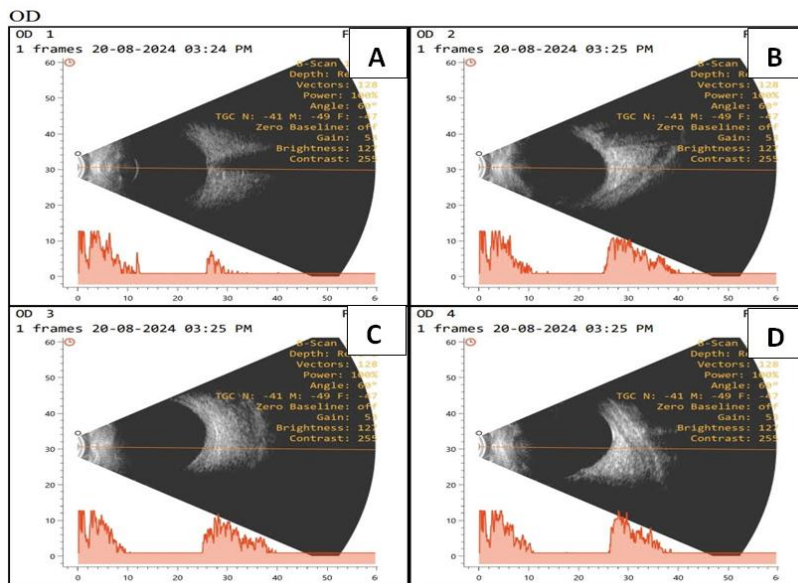


Fig. 7: OD (A, B, C, D) depicts a normal B-scan ultrasound report.

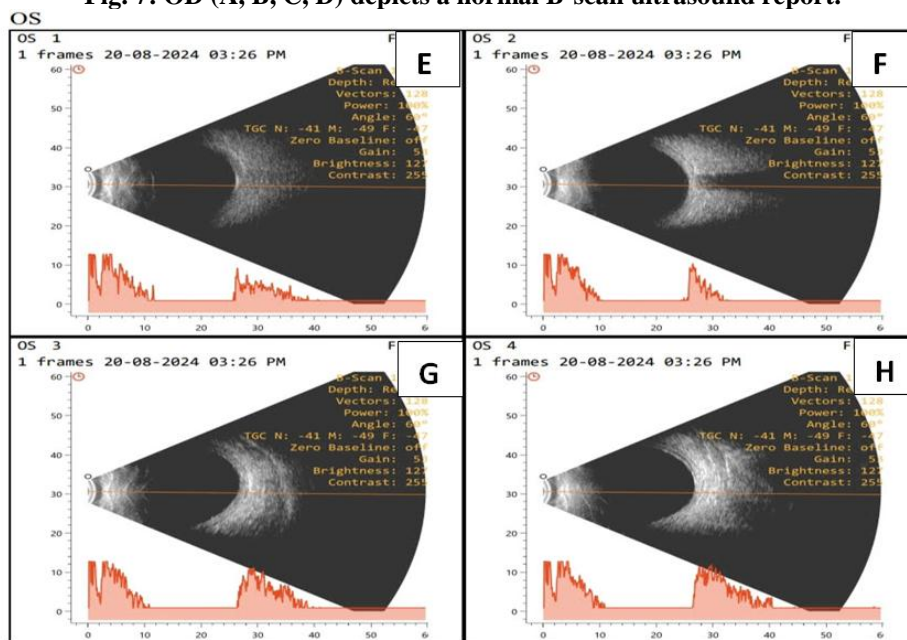
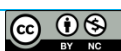

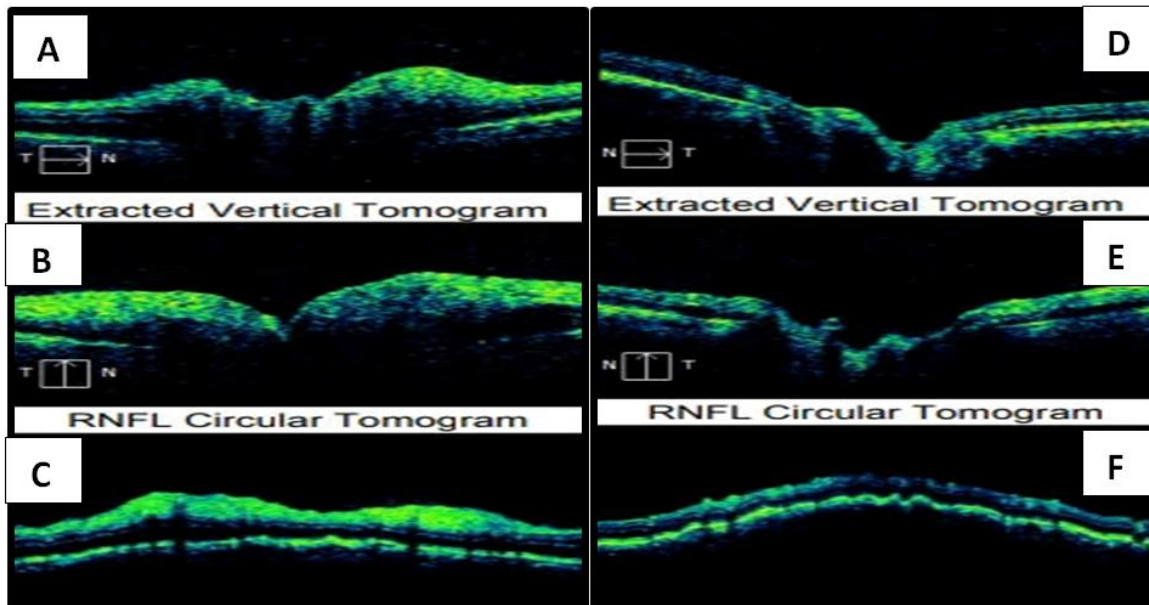
Fig. 8: OS (E,F,G,H) depicts a normal B-scan ultrasound report

In the OCT retinal nerve fiber layer (RNFL) scan of the right eye, the average RNFL thickness was normal at 80  $\mu\text{m}$ , with reduced RNFL symmetry at 51%. The rim area and disc area were both normal, with an average cup-to-disc (CD) ratio of 0.56 mm and a normal cup volume.

In the OCT RNFL scan of the left eye, the average RNFL thickness was reduced to 63  $\mu\text{m}$ , with reduced RNFL symmetry at 51% and a reduced rim area of 0.81  $\text{mm}^2$ . The average CD BERatio was reduced to 0.77 mm, the vertical CD ratio was reduced to 0.74mm, and the cup volume was normal.

The OCT RNFL results indicated that the reduced RNFL symmetry in the right eye was due to ischemic optic neuropathy and chronic angle closure glaucoma, while the reduced RNFL thickness in the left eye was attributed to optic atrophy and chronic angle closure glaucoma. Bansal *et al.* also concluded that RNFL thinning is present in optic atrophied eyes and relatively normal RNFL thickness in another eye [22]. In our study, the RNFL thickness of the right eye was relatively normal except for RNFL symmetry thinning due to the patient having Parkinson’s disease. Elan War *et al.* concluded that in Parkinson’s disease, the thickness of RNFL, the ganglion cell layer, and the peripapillary thickness reduced [23].



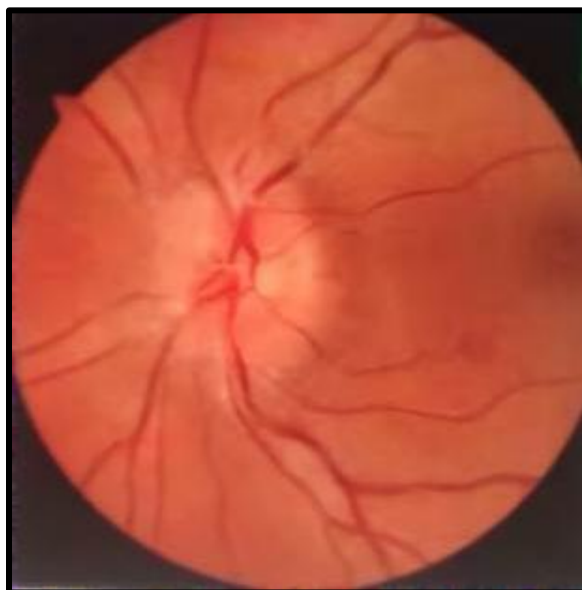


**Fig.9: OD(A, B, C) OCT RNFL depicts Papilledema**

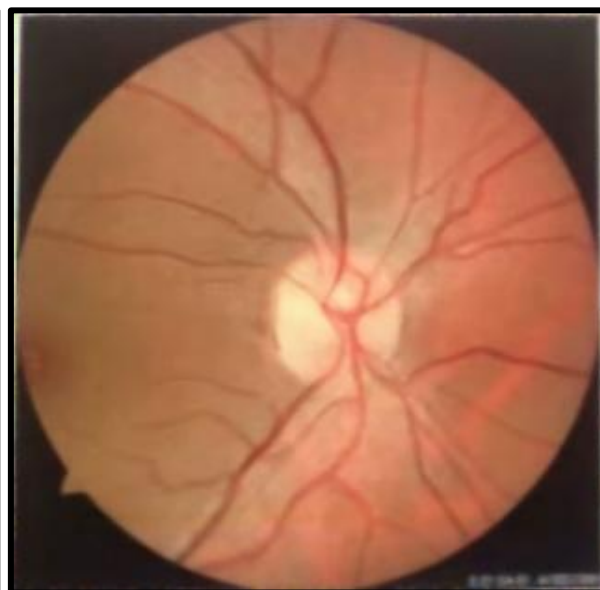The fundus examination identified optic disc edema and sphincter hemorrhages in the RE NAION and consecutive optic atrophy in the LE due to NAION

**Fig.10: OS (D, E, F) OCT RNFL depicts optic atrophy**

resulting from prior primary angle-closure glaucoma (PACG) and age-related nuclear cataract in both eyes (BE).



**Fig-11: RE Papilledema**



**Fig-12: LE Optic atrophy**

David *et al.*, in their studies, revealed that a common cause for PFKS was due to NAION. There is no generally accepted treatment for NAION, but oral corticosteroids have shown improvements in visual acuity and visual fields in treated and untreated cases [24].

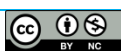
**CONCLUSION**

The patient with NAION was closely monitored, and no relapses have been observed. As of now, there is still no universally accepted treatment for this condition. After the intravenous prednisolone course and tablet

Wysolone 20 mg and under anti-glaucoma medication, the patient’s UCVA was increased to 6/24 and 6/18. After 3 weeks of follow-up, the patient’s UCVA was increased to 6/18 in both eyes.

**REFERENCES**

1. Schatz, N. J., & Smith, J. L. (1967). Non-tumour causes of the foster Kennedy syndrome. *Journal of Neurosurgery*, 27(1), 37-44.
2. Watnick, R. L., & Trobe, J. D. (1989). Bilateral optic nerve compression as a mechanism for the



- foster Kennedy syndrome. *Ophthalmology*, 96(12), 1793-1798.
3. Parafita-Fernández, A., Sampil, M., Cores, C., Cores, F. J., & Viso, E. (2015). Foster Kennedy Syndrome: An Atypical Presentation. *Optometry and vision science: official publication of the American Academy of Optometry*, 92(12), e425–e430.
  4. Patil, A., Takkar, A., Goyal, M., Singh, R., & Lal, V. (2017). Sequential NAION presenting as pseudo-foster Kennedy syndrome. *Journal of the Neurological Sciences*, 376, 49–51.
  5. Gupta, Amod M.D.; Jalali, Subhadra M.D.; Bansal, R. K. M.D.; Grewal, S. P. S. M.D. (1990) Anterior Ischemic Optic Neuropathy and Branch Retinal Artery Occlusion in Cavernous Sinus Thrombosis *Journal of Clinical Neuro-Ophthalmology* 10(3):p 193-196.
  6. Limaye, S. R., & Adler, J. (1990). Pseudo-Foster Kennedy syndrome in a patient with anterior ischemic optic neuropathy and a non-basal glioma. *Journal of Clinical neuro-ophthalmology*, 10(3), 188–192.
  7. Tamai, H., Tamai, K., & Yuasa, H. (2000). Pachymeningitis with pseudo-foster Kennedy syndrome. *American journal of ophthalmology*, 130(4), 535–537.
  8. Visa Reñé, N., & Paredes Carmona, F. (2019). Pseudo-Foster Kennedy syndrome due to idiopathic intracranial hypertension. Síndrome de pseudo-Foster Kennedy por hipertensión intracraneal idiopática. *Archivos de la Sociedad Espanola de Oftalmologia*, 94(12), 598–601.
  9. Daniel Lamoureux, Paul Savioli, Leland Dhurjon, Vishaal Bhambhwani, Chronic subdural hematoma presenting as Pseudo-Foster Kennedy Syndrome: Case report and review of the literature, *JFO Open Ophthalmology*, Volume 3, 2023, 100029, ISSN 2949-8899.
  10. Petramfar, P., Hosseinzadeh, F., & Mohammadi, S. S. (2016). Pseudo-Foster Kennedy Syndrome as a Rare Presentation of Vitamin B12 Deficiency. *Iranian Red Crescent Medical Journal*, 18(6), e24610
  11. Rahhal-Ortuño M, Fernández-Santodomingo AS, Marín-Payá E, Aguilar-González M, Villena-Alvarado CK, Ramos-González L. Hyperhomocysteinemia and low folate levels as the only risk factors in pseudo-Foster Kennedy syndrome. *J Fr Ophtalmol*. 2021 Jun;44(6):e353-e356.
  12. Bhatnagar, Kavita & Raulji, Charu & Kumar, Pooja & Solanki, Dependar. (2014). Pseudo Foster Kennedy Syndrome secondary to uncontrolled hypertension and diabetes mellitus: A case report. *Medical Journal of Dr. D.Y. Patil University*. 7. 385. 10.4103/0975-2870.128999.
  13. Vignesh, A. P., & Srinivasan, R. (2015). Pseudo-Foster Kennedy Syndrome Due to Diabetic Papillopathy. *Adv Ophthalmology Vis Syst*, 2(4), 00050.
  14. Biousse, V., Skibell, B. C., Watts, R. L., Loupe, D. N., Drews-Botsch, C., & Newman, N. J. (2004). Ophthalmologic features of Parkinson's disease. *Neurology*, 62(2), 177–180.
  15. Mohana Devi, S., Mahalaxmi, I., Aswathy, N. P., Dhivya, V., & Balachandar, V. (2020). Does the retina play a role in Parkinson's Disease? *Acta neurologica Belgica*, 120(2), 257–265.
  16. Chorostecki, J., Seraji-Bozorgzad, N., Shah, A., Bao, F., Bao, G., George, E., Gorden, V., Caon, C., Frohman, E., Bhatti, M. T., & Khan, O. (2015). Characterization of retinal architecture in Parkinson's disease. *Journal of the Neurological Sciences*, 355(1-2), 44–48.
  17. Hajee, M. E., March, W. F., Lazzaro, D. R., Wolintz, A. H., Shrier, E. M., Glazman, S., & Bodis-Wollner, I. G. (2009). Inner retinal layer thinning in Parkinson's disease. *Archives of ophthalmology (Chicago, Ill.: 1960)*, 127(6), 737–741.
  18. Verghese, S., Berkowitz, S. T., Shah, V. M., Shah, P., Priya, S., Saravanan, V. R., Narendran, V., & Selvan, V. A. (2022). Assessment of retinal manifestations of Parkinson's disease using spectral domain optical coherence tomography: A study in Indian eyes. *Indian journal of ophthalmology*, 70(2), 448–452.
  19. Garcia-Martin, E., Satue, M., Otin, S., Fuertes, I., Alarcia, R., Larrosa, J. M., Polo, V., & Pablo, L. E. (2014). Retina measurements for diagnosis of Parkinson's disease. *Retina (Philadelphia, Pa.)*, 34(5), 971–980.
  20. Desai, N., Yong, R. L., Doshi, A., & Rucker, J. C. (2015). Pseudo-Foster-Kennedy syndrome with optic nerve compression by the gyrus rectus. *Neurology*, 85(4), 385..
  21. F. Semeraro, E. Forbice, S. Duse, C. Costagliola, Pseudo-Foster Kennedy syndrome in a young woman with meningioma infiltrating the superior sagittal sinus, *Clinical Neurology and Neurosurgery*, Volume 114, Issue 3, 2012, Pages 272-274, ISSN 0303-8467,
  22. Bansal, S., Dabbs, T., & Long, V. (2008). Pseudo-Foster Kennedy Syndrome due to unilateral optic nerve hypoplasia: a case report. *Journal of medical case reports*, 2, 86.
  23. Elan war, R., Al Masry, H., Ibrahim, A., Hussein, M., Ibrahim, S., & Masoud, M. M. (2023). Retinal functional and structural changes in patients with Parkinson's disease. *BMC neurology*, 23(1), 330.
  24. David, C., Suvac, E., Tăbăcaru, B., & Stanca, T. H. (2016). Pseudo-Foster Kennedy Syndrome - a case report. *Romanian journal of ophthalmology*, 60(4), 270–274.



## ACRONYMS

- ✚ AAION -Arteritic Anterior Ischemic Optic Neuropathy
- ✚ DM - Diabetes Mellitus
- ✚ GHT - Glaucoma Hemi field Test
- ✚ HFA- Humphrey Field Analyser
- ✚ NAION - Non-Arteritic Anterior Ischemic Optic Neuropathy
- ✚ OCT - Optical Coherence Tomography
- ✚ PACG - Primary Angle Closure Glaucoma
- ✚ PFKS - Pseudo Foster Kennedy Syndrome
- ✚ PI - Peripheral Iridotomy
- ✚ RNFL - Retinal Nerve Fiber layer
- ✚ SITA - Swedish Interactive Threshold Algorithm
- ✚ STIR - Short TI (Tau) Inversion Recovery
- ✚ UCVA - Uncorrected Visual Acuity

