

## Neodymium Doped Yttrium Aluminum Garnet (Nd: YAG) Laser Physics in Ophthalmology

Dhanisha JL<sup>1</sup>, Heber Anandan<sup>2</sup>, Vinitha B<sup>3</sup>

<sup>1</sup>Associate Professor & Principal, Dr. Agarwal's Institute of Optometry, Tirunelveli, Tamil Nadu, India

<sup>2</sup>Addl. DG of Research, Dr. Agarwal's Institute of Optometry, Tirunelveli, Tamil Nadu, India

<sup>3</sup>Asst. Professor, Dr. Agarwal's Institute of Optometry, Tirunelveli, Tamil Nadu, India

\*Corresponding Author: Dhanisha JL | Received: 17.06.2025 | Accepted: 14.08.2025 | Published: 31.08.2025

**Abstract:** Most medical areas have experienced the emergence of laser technology. Laser treatment is widely used in ophthalmology to manage a variety of eye diseases. For instance, it is used to treat posterior capsular opacification (PCO) following cataract surgery and to perform peripheral iridotomy in angle-closure glaucoma. Posterior capsular opacification is also referred to as recurrent cataract or secondary cataract. Additional operations include vitreolysis, peripheral iridotomy, anterior capsule capsulorhexis, corneal stromal reinforcement, and laser posterior capsulotomy, using YAG. Because of the growing demand for non-invasive ocular inventions, the Nd: YAG (Neodymium doped Yttrium Aluminum Garnet) laser plays a crucial role in enhancing visual health. The review explores the fundamental physics of Nd:YAG lasers and their purposes in the field of ophthalmology.

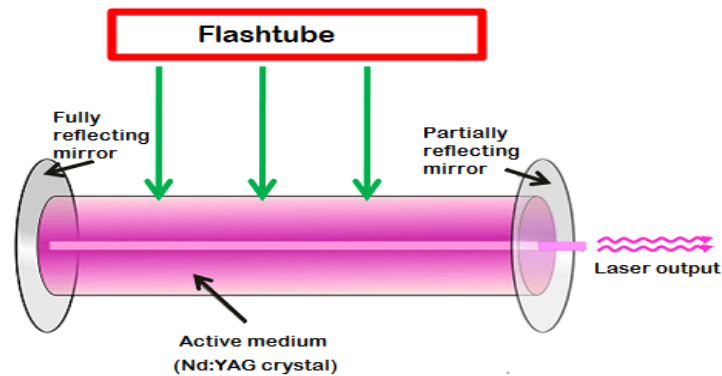
**Keywords:** Nd: YAG laser, Posterior capsular opacification (PCO), Glaucoma; iridotomy, capsulotomy, Laser principle iridotomy (LPI).

**Citation:** Dhanisha JL *et al.* Neodymium Doped Yttrium Aluminum Garnet (Nd: YAG) Laser Physics in Ophthalmology. Grn Int J Apl Med Sci, 2025 Jul-Aug 3(4): 221-225.

## INTRODUCTION

The laser is characterized as a device that magnifies light through stimulated emission of radiation. The acronym describes the basic principle behind how a laser works-amplifying light by using stimulated emission. A laser that releases a photon that is amplified so the emitted photon becomes monochromatic, coherent, high-intensity, polarized light. It is a solid-state laser; yttrium aluminum garnet crystal laced with neodymium acts as the laser's lasing material [1]. The Nd: YAG laser was used in ophthalmology in the 1980s due to its ability to penetrate the eye's transparent area without affecting other good tissues. There are so many lasers used in ophthalmology, such as Nd: YAG laser, Argon laser, Diode laser, Krypton red laser, Green laser, Excimer laser, etc. The Nd: YAG lasers emit infrared light at a wavelength of 1064nm that are frequently used due to their ability to precisely and effectively treat various conditions, particularly after cataract surgery. And their ability to break up tissue through photodisruption, creating a shockwave, makes them ideal for procedures like posterior capsulotomies, iridotomies, and floater

treatment. The laser is used in ophthalmology for various advantages. The mechanism operates on the principle of photodisruption, generating a burst of energy capable of cutting or disrupting ocular tissue. The working of the laser is that the crystal is pumped by a lamp of light or a diode, which emits the neodymium ions, allowing them to produce a laser light. The 1064nm wavelength is absorbed by melanin, hemoglobin, or water, making it useful for a variety of ophthalmic treatments. The physics behind the content works by using ions that are placed in a crystalline matrix to create light from a laser. The crystalline matrix transfers energy between the ions, whereas the ions or dopants supply the electrons for the excitation. YAG lasers are widely employed in ophthalmology due to their versatility in performing eye-related procedures. Primarily, it used to address the issues related to cataract surgery and glaucoma treatment Nd: YAG laser was developed in 1964 by E. Joseph, Richard G. Smith, and their colleagues. The laser is used in ophthalmology applications that were invented by the department of ophthalmology by Dr. Aron-Rose and Franz Fankhauser in the early 1980s [2].

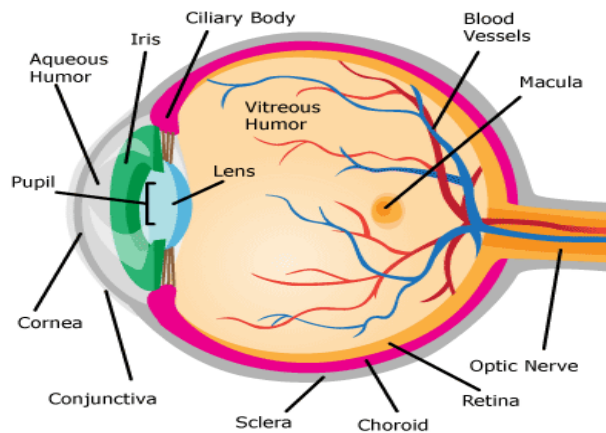


**Figure-1: Construction of Nd: YAG laser**

**ACTION OF A LASER LIGHT ON THE EYE:**

Laser light is utilized in ophthalmology because it possesses coherent, focused, monochromatic, and high-energy characteristics. Nowadays the laser surgery is a more adaptable tool and it is accurate and has fewer complications than conventional surgery [3]. The laser has been frequently employed in ophthalmology over the past ten years. The most effective application of the neodymium-doped yttrium aluminum garnet crystal laser is for the treatment of posterior capsulotomy (PCO). The primary application for this laser is

iridectomy; yet it may also be used to cut vitreous adhesion bands. The other lasers, including argon lasers, are frequently used to seal and burn bleeding blood vessels to treat diabetic retinopathy. Thermal lasers are utilized in glaucoma treatment by either opening the drainage channels or preventing them from becoming blocked. The diode laser is used to treat conditions like retinopathy of prematurity (ROP). For the treatment of retinal surgery, the krypton laser is frequently employed [4].



**Figure-2: Anatomy of the eye**

**CLINICAL SIGNIFICANCE:**

More details about applications are as follows:

- Posterior capsular opacification(PCO)
- Anterior capsulotomy
- Peripheral iridotomy
- Vitreolysis
- Corneal stromal reinforcement

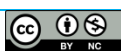**POSTERIOR CAPSULAR OPACIFICATION:**

Secondary cataract, or the after cataract, is the additional name for posterior capsular opacification. Following cataract surgery, the natural lens's remaining cells may occasionally proliferate, resulting in PCO, or cloudiness of the posterior capsule [5]. This is a frequent post-cataract surgery difficulty. The specified

capsule gets punctured precisely using a YAG laser. The opening function is to let laser light propagate and improve the patient's vision. in the opacified capsule. With exact targeting, the laser breaks through opacities and strengthens vision without affecting various parts of the eye [2]. Posterior capsular opacification (PCO), a frequent issue after cataract surgery, is typically treated with Nd: YAG laser capsulotomy. Numerous investigations have shown that the therapy has a high success rate. In very rare cases, the laser can damage the intraocular lens (IOL) or cause it to move [6].

**ANTERIOR CAPSULOTOMY:**

The Nd: YAG laser is employed during anterior capsulotomy, also referred to as capsulorhexis, to open



or expand the anterior lens capsule that surrounds the eye's natural lens. And it is used to treat the capsular phimosis, that known as scarring and capsular block syndrome after a cataract surgery. It is also used to reduce the intralenticular pressure in mature cataract [7]. This method is done because after cataract surgery, the lens capsule can sometimes shrink or contract, which can lead to a condition called capsular phimosis. That contraction can deny or restrict the vision, and it causes glare or blurred vision. By carefully removing the capsule, the Nd: YAG laser makes a tiny hole that may be used to extract it. In summary, the anteriorcapsulotomy using Nd: YAG laser is a surgical procedure that can be performed to improve the vision of patients who have suffered from capsular contraction or phimosis after cataract surgery [8].

#### **PERIPHERAL IRIDOTOMY:**

This mechanism is used to create a meticulous opening in the peripheral iris to improve the flow of fluid from behind the iris directly to the anterior chamber of the eye and reduce intraocular pressure. The Nd: YAG laser is frequently employed in the procedure known as peripheral iridotomy. This adjective method is called Laser Peripheral Iridotomy (LPI). The laser peripheral iridotomy is used to prevent or treat a sudden rise in pressure inside the eye that also known as acute glaucoma. It is used to manage chronic glaucoma by improving drainage angle access. By allowing the fluid to exit from beneath the iris, the iridotomy relieves pressure and shields against optic nerve injury. For angle-closure glaucoma and secondary angle-closure conditions, LPI is a standard treatment method. The patients are typically monitored after laser peripheral iridotomy (LPI) to check Intraocular pressure (IOP), visual acuity, and angle status [1].

#### **VITREOLYSIS:**

The treatment of eye floaters often involves the use of the Nd: YAG laser. The term vitreous floaters refer to the area of vision that appears black or grey or that resembles strings that move across the eyes [9]. The eyes are susceptible to the uncomfortable problems termed vitreous floaters. The procedure where laser energy is directed into a floater, the excessive heat causes the floater is break down and vaporize the floater. The floater is also known as a vitreous opacity, is placed within the eye's vitreous humor. Whereas vitrectomy is a surgical procedure used to remove floaters and vitreous gel, Nd: YAG laser vitreolysis offers a non-invasive substitute. Generally, it is safe and effective, but it has some potential complications that include retinal tears, retinal detachments, glaucoma, and posterior capsular opacification. Laser eye floater removal is a term utilized to signify the YAG laser vitreolysis approach. The approach is quite successful and involves vaporizing the eye floaters via a nano-pulsed YAG laser. This approach offers ideal patient satisfaction and a low risk of consequences [10].

#### **CORNEAL STROMAL REINFORCEMENT:**

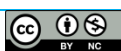
The anterior stromal puncture (ASP) with an Nd:YAG laser is an effective and safe procedure for treating recurrent corneal erosion(RCE). RCE is defined as the condition in which the cornea repeatedly breaks down and causes vision problems [3, 11]. It can enhance or improve the frequency of attacks and the intensity of the pain. The disorder known as recurrent corneal erosion is characterized by the constant breakdown of the corneal epithelium, commonly referred to as the outermost layer. The Nd: YAG laser is used to generate a small crack in the corneal stroma. The corneal stroma is located underneath the cornea's outermost layer of epithelium. The break is designed to improve the gluing between the epithelium and the stroma, which can be used to prevent further erosions. It can deliver a stronger attachment. The main benefits of this method are distinct from other methods like anterior stromal puncture with a needle; the Nd: YAG laser offers more accuracy and reproducible punctures, and it potentially leads to less stromal scarring [12,13].

#### **ADVANTAGES OF ND: YAG LASERS:**

Nd:YAG lasers in ophthalmology offer advantages, such as being a non-invasive procedure, generally less time-consuming than other methods, and improving patient vision outcome, particularly in the treatment of capsulotomy and iridotomy. The Nd:YAG capsulotomy can improve visual sight and reduce the glare and contrast sensitivity problems, especially after the cataract surgery [14]. It can reduce the need for hospitalization. In contrast to other laser procedures, Nd: YAG laser treatment is associated with minimal pain and inflammation. Despite little impact on the surrounding tissues, it may perfectly focus on the specifically intended parts of the eye [15]. The Nd: YAG laser in ophthalmology is valuable for treating the disorders arising after cataract surgery, including posterior capsular opacification (PCO), and for the treatment of glaucoma. The process is non-invasive, relatively quick, and has low complication rates [16]. The Nd: YAG laser is used to cut and manipulate intraocular structures. Compared to other surgeries, laser treatment is a faster option that requires less time. The Nd: YAG laser procedure can be cost-effective compared to the surgical procedure [20].

#### **THE DRAWBACKS OF YAG LASERS:**

It can increase the intraocular pressure (IOP) after cataract surgery. The Nd:YAG laser can potentially damage the intraocular lens (IOL), especially if the laser is not focused properly or if the IOL is made of certain materials. Although very rare cases, there is a small risk of infections, especially if the eye is not properly prepared before the treatment. The risk associated with peripheral iridotomy is that it can temporarily extent the eye pressure, bleeding, and hotness at the laser site. Rarely, the iridotomy may be closer or cause visual disturbance, like glare or flashes [21].



## INTERRELATIONSHIP BETWEEN EYE, PHYSICS, AND NEODYMIUM YTTRIUM ALUMINUM GARNET (Nd: YAG) LASER:

The physics principle of the Nd: YAG laser is stimulated emission. Normally, in lasers, two emissions occur. These are spontaneous emission and stimulated emission. In spontaneous emission, the excited electron releases a single photon by returning to the ground state. But in stimulated emission, the excited photon releases additional photons by returning to the ground state [17]. Nd: YAG crystal is made up of yttrium aluminum garnet doped with neodymium ions. Their properties include high gain, good thermal conductivity, and high mechanical strength. The excited neodymium ions release photons, which stimulate further emission at 1064nm wavelength. The advantages of the Nd: YAG laser include that it can produce high peak powers, a high-quality beam with good focusability, and it can be used in various applications from medicine to material processing. Nd: YAG lasers are used in material processing (cutting, welding, polishing, and engraving metal and plastic materials) [18]. The main application of the Nd: YAG laser is in ophthalmology for the treatment of posterior capsulotomy (PCO), iridotomy, and peripheral iridotomy. The benefits of using Nd: YAG laser is minimally invasive, precise tissue disruption that YAG laser provide precise control over tissue disruption, effective treatment by using Nd: YAG lasers are effective in treating various ophthalmic conditions, the laser treatment procedures have low risk of complications, that also can significantly improve vision and quality of life. The Nd: YAG laser is mostly preferred in ophthalmology because of that laser is highly safe, efficacy, and has minimal side effects [19].

## DISCUSSION

Gilmour M.A. reviewed the introduction of lasers in veterinary ophthalmology, and he developed the uses of diode lasers and their impact on veterinary ophthalmology. He used this laser because of the affordability, portability of diodes. Also, he proves that using the diode laser provides more benefits to future applications [7]. Aslam T.M *et al.*, states that by using Nd: YAG laser in the removal of cataract in the eye by the treatment of posterior capsular opacification (PCO) [8]. Also, Karahan, E., Er, D., *et al.*, states the treatment of PCO using Nd: YAG laser in the section of ophthalmology [22]. Similarly, Borkenstein *et al.* focus on two common ophthalmic applications of the Nd: YAG laser, that is, the laser peripheral iridotomy and the other is posterior capsulotomy. They also discuss the technique's history, complications, complaints, and future uses [1]. Ludwig, G.D, *et al.*, defined the uses of Nd: YAG laser in the treatment of vitreous floaters, and their aim of this review is to examine the efficiency and safety in the treatment of vitreous floaters, by using YAG laser vitreolysis and they show a result that the Nd: YAG vitreolysis improves the visual power of the

patients [10]. Tsai T.Y *et al.*, prove that using an Nd: YAG laser with anterior stromal puncture is an effective and very simple treatment procedure for the treatment of recurrent corneal erosion, and they prove this method can ameliorate the attack frequency and reduce the pain [11].


Our study describes the uses of the Nd: YAG laser in various treatments and disorders in the field of ophthalmology. Compared to other review articles, they state particular disorders and their treatment procedures, but in this review, the various lasers involved in the various ophthalmic disorders, and especially the Nd: YAG laser principle, applications, and the benefits of using Neodymium-doped Aluminum Garnet Laser in ophthalmology are discussed.

## CONCLUSION

The Nd:YAG (Neodymium doped Yttrium Aluminum Garnet) laser has become a crucial tool in ophthalmology due to its precise and noninvasive properties. Understanding the physics behind the laser, especially its wavelength, energy delivery, and focusing on the tissues it can minimize the complaints. The laser operates at a wavelength of 1064nm, and the laser delivers high-intensity, short-duration pulses that enable photo-disruption to treat the various posterior segment conditions. The technique is extensively applied in cases of posterior capsule opacification that occur after cataract surgery. It is generally safe and effective, while the procedures have minimal complications, including it can increasing the intraocular pressure (IOP) and retinal damage.

## REFERENCES

1. Borkenstein, A. F., &Borkenstein, E. M. (2024). Neodymium-doped yttrium aluminum garnet (Nd: YAG) laser treatment in ophthalmology: a review of the most common procedures,Capsulotomy and Iridotomy. *Lasers in Medical Science*, 39(1), 167.
2. Krauss, J. M., &Puliafito, C. A. (1995). Lasers in ophthalmology. *Lasers in surgery and medicine*, 17(2), 102-159.
3. Bessette, F. M., & Nguyen, L. C. (1989). Laser light: its nature and its action on the eye. *CMAJ: Canadian Medical Association Journal*, 141(11), 1141.
4. Zhang, A. Y.,Kumar, D., &Tripathy, K. (2023). Laser Principles in Ophthalmology. In StatPearls. Statpearls Publishing.
5. Weiblinger R. P. (1986). Review of the clinical literature on the use of the Nd:YAG laser for posterior capsulotomy. *Journal of cataract and refractive surgery*, 12(2), 162-170.
6. Stark, W. J., Worthen, D., Holladay, J. T., & Murray, G. (1985). Neodymium: YAG lasers: an FDA report. *Ophthalmology*, 92(2), 209-212.



7. Gilmour, M. A. (2002). Lasers in ophthalmology. *Veterinary Clinics: Small Animal Practice*, 32(3), 649-672.
8. Aslam, T. M., Devlin, H., & Dhillon, B. (2003). Use of Nd: YAG laser capsulotomy. *Survey of Ophthalmology*, 48(6), 594-612.(2)
9. Aron-Rosa, D., & Greenspan, D. A. (1985). Neodymium: YAG laser vitreolysis. *International Ophthalmology Clinics*, 25(3), 125-134.
10. Ludwig, G. D., Gemelli, H., Nunes, G. M., Serracarbassa, P. D., & Zanotele, M. (2021). Efficacy and safety of Nd: YAG laser vitreolysis for symptomatic vitreous floaters: a randomized controlled trial. *European journal of ophthalmology*, 31(3), 909-914.
11. Tsai, T. Y., Tsai, T. H. Hu, F. R., & Hou, Y. C. (2009). Recurrent corneal erosions treated with anterior stromal puncture by neodymium: yttrium-aluminum-garnet laser. *Ophthalmology*, 116(7), 1296-1300.
12. Geggel, H. S. (1990). Successful treatment of recurrent corneal erosion with Nd: YAG anterior stromal puncture. *American journal of ophthalmology*, 110(4), 404-407.
13. Geggel, H. S., & Maza, C.E. (1990). Anterior Stromal puncture with the Nd: YAG laser. *Investigative ophthalmology & visual science*, 31(8), 1555-1559.
14. Moisseiev, J., Bartov, E., & Blumenthal, M. (1985). Neodymium-YAG laser, a non-invasive technique for cutting intraocular tissues. *Harefuah*, 108(9), 433-435.
15. Radda, T. M., Gnad, H. D., & Freyler, H. (1985). Use of the neodymium YAG laser following posterior chamber lens implantation. *Klinische Monatsblätter für Augenheilkunde*, 187(5), 427-429.
16. O'Neil, D., Gregson, R., & McHugh, D. (1992). Current uses of ophthalmic lasers. *British Medical Journal*, 304(6835), 1161-1165.
17. Barnes, N. P., & Walsh, B. M. (2002). Amplified spontaneous emission-application to Nd: YAG lasers. *IEEE journal of quantum electronics*, 35(1), 101-109.
18. Dumitras, D. C. (Ed.). (2012). *Nd YAG Laser*. BoD-Books on Demand.
19. Karahan, E., Er, D., & Kaynak, S. (2014). An overview of Nd: YAG laser capsulotomy. *Medical hypothesis, discovery and innovation in ophthalmology*, 3(2), 45.
20. Lyle, W. M., Cullen, A. P., & Charman, W. N. (1993). Role of lasers in eye care. *Optometry and vision science*, 70(2), 136-151.
21. Khambhiphant, B., Liamsirjarern, C., & Saehout, P. (2015). The effect of Nd: YAG laser treatment of posterior capsule opacification on anterior chamber depth and refraction in pseudophakic eyes. *Clinical ophthalmology (Auckland, N. Z.)*, 9, 557-561.
22. Karahan, E., Er, D., & Kaynak, S. (2014). An Overview of Nd:YAG Laser Capsulotomy. *Medical hypothesis, discovery & innovation ophthalmology journal*, 3(2), 45-50.

#### **Acronyms:**

- Nd:YAG-Neodymium doped Yttrium Aluminum Garnet
- PCO-Posterior Capsular Opacification
- LPI-Laser Peripheral Iridotomy
- ROP-Retinopathy of Prematurity
- IOL-Intraocular Lens
- ASP-Anterior Stromal Puncture
- RCE-Recurrent Corneal Erosion
- IOP-Intraocular Pressure

