

Research Article

DOI: 10.62046/gijams.2024.v02i03.004

Comparative Analysis of Functional and Surgical Outcomes in Humeral Shaft Fractures: Interlocking Nailing vs. Dynamic Compression Plating

Dr. Erfanul Huq Siddiqui¹, Dr. Sheikh Forhad², Dr. Mohammad Al Mamun³, Dr. Sharif Md. Musa⁴, Dr. A. K. Al Miraj⁵, Dr. Mohammad Sazzad Hossain⁶

¹Assistant Professor, Department of Orthopaedic Surgery, Bangabandhu Sheikh Mujib Medical University (BSMMU), Dhaka, Bangladesh

²Assistant Professor, Department of Orthopaedic Surgery, Bangabandhu Sheikh Mujib Medical University (BSMMU), Dhaka, Bangladesh

³Assistant Professor, Department of Cardiology, Bangabandhu Sheikh Mujib Medical University (BSMMU), Dhaka, Bangladesh

⁴Assistant Professor, Department of Orthopaedic Surgery, Bangabandhu Sheikh Mujib Medical University (BSMMU), Dhaka, Bangladesh

⁵Research Assistant, Department of Vascular Surgery, Bangabandhu Sheikh Mujib Medical University (BSMMU), Dhaka, Bangladesh

⁶Assistant Professor, Department of Orthopaedic Surgery, Bangabandhu Sheikh Mujib Medical University (BSMMU), Dhaka, Bangladesh

*Corresponding Author: Dr. Erfanul Huq Siddiqui | Received: 19.04.2024 | Accepted: 08.05.2024 | Published: 27.06.2024

Abstract: Background: Humeral shaft fractures account for about 3-5% of all fractures, with a 3.87% incidence in Bangladesh. These fractures often respond well to non-operative treatments like casts and braces due to the humerus's ability to tolerate malunion, leading to satisfactory outcomes. However, surgery is necessary for specific cases, including open, segmental, or pathological fractures, and when conservative treatment fails. Surgical options, like dynamic compression plates and interlocking nails, allow for quicker recovery but carry risks, including nerve damage and mechanical failure. Interlocking nails offer a less invasive option with better biomechanics but may cause shoulder complications. **Aim of the study:** This study aims to compare the functional and surgical outcomes of patients treated with dynamic compression plating versus those treated with interlocking nailing, to determine the most effective approach for managing humeral shaft fractures. **Methods:** This cross-sectional study in Department of Orthopaedic Surgery, Bangabandhu Sheikh Mujib Medical University, Bangladesh, conducted from [11/12/2022] to [20/12/2023], involved 60 patients with humerus diaphyseal fractures, divided into two groups: Group A (30 patients treated with dynamic compression plating) and Group B (30 patients treated with interlock nailing). Participants were selected based on strict inclusion/exclusion criteria, and informed consent was obtained. The study evaluated various clinical factors using standard surgical techniques. Data analysis was performed using SPSS software, with significance determined at $p < 0.05$. **Result:** A prospective observational study at a tertiary care center involved 60 patients with humeral diaphyseal fractures, divided into two groups: 30 treated with dynamic compression plating (Group A) and 30 with interlocking nailing (Group B). Most participants were under 30, predominantly male, with no significant differences in age or gender distribution. Group B showed better blood management, while Group A had superior shoulder function but more shoulder stiffness. Both groups had similar operative times, elbow performance, and fracture union rates. Neurovascular deficits were more common in Group A. The study highlights different outcomes between the two treatment methods. **Conclusion:** This study evaluated clinical outcomes in patients, primarily under 30 years old, with a higher incidence in males and right-sided fractures. Dynamic compression plating led to longer surgeries, more significant blood loss, higher union rates, and more shoulder stiffness. Interlock nailing resulted in fewer neurovascular deficits but reduced shoulder function postoperatively.

Keywords: Humeral Shaft Fractures, Interlocking Nailing, Dynamic Compression Plating, Functional and Surgical Outcomes.

Citation: Erfanul Huq Siddiqui *et al.*. Comparative Analysis of Functional and Surgical Outcomes in Humeral Shaft Fractures: Interlocking Nailing vs. Dynamic Compression Plating. Grn Int J Apl Med Sci, 2024 May-Jun 2(3): 97-104.

INTRODUCTION

Fractures of the humeral shaft are relatively common, accounting for approximately 3-5% of all fractures [1]. In Bangladesh, a retrospective analysis at Bangabandhu Sheikh Mujib Medical College in Faridpur revealed that diaphyseal fractures of the humerus accounted for 3.87% of all reported fracture cases [2]. These fractures are particularly notable among long bone injuries due to their exceptional outcomes when treated with non-operative methods. These conservative treatments include approaches such as hanging casts, functional braces, Velpeau dressings, coaptation splints, and abduction casts [3-5]. The success of these methods can largely be attributed to the humerus's unique ability to tolerate malunion, which often results in satisfactory functional outcomes even when perfect anatomical alignment is not achieved. However, not all humeral shaft fractures are amenable to conservative management. There are specific clinical situations where surgical intervention becomes necessary. These include cases of open fractures, segmental fractures, pathological fractures, fractures associated with vascular injuries, bilateral humerus fractures, polytrauma, and radial nerve palsy that occurs after fracture manipulation. Additionally, neurological deficits resulting from penetrating injuries, fractures with unacceptable alignment, and the failure of conservative treatment to achieve union are also indications for operative management [6]. One of the drawbacks of non-operative treatment is the requirement for prolonged immobilization, which can lead to significant shoulder joint stiffness and discomfort for the patient [7,8]. Moreover, despite the overall success of conservative methods, non-union occurs in up to 10% of these fractures, and addressing this complication can be particularly challenging [9-11]. This risk of non-union, combined with the inconvenience and complications associated with long-term immobilization, has led to a growing interest in surgically managing even relatively simple humeral shaft fractures. Surgical treatment allows for earlier mobilization, reduces the risk of joint stiffness, and facilitates a quicker return to daily activities and work [12,13]. The primary surgical methods employed in treating humeral shaft fractures involve using dynamic compression plates (DCP) or interlocking nails (ILN). Plate and screw fixation has traditionally been the method of choice and continues to be regarded as the gold standard for surgical management of these fractures [14]. However, this method has its challenges. The procedure requires extensive dissection, which can endanger the radial nerve, and there is also a risk of mechanical failure, particularly in patients with osteopenic bone. Recent advancements in surgical techniques and the success of intramedullary nailing in treating other long bone fractures have sparked increased interest in using humeral intramedullary nails for these fractures. Interlocking nailing is a less invasive procedure that offers improved biomechanics

and load-sharing characteristics. Additionally, fractures managed with ILN are more likely to achieve union, as the procedure does not involve periosteal stripping, and the reaming process can act as an autograft. However, this method has as it can lead to shoulder complications [15]. Given these factors, this study aims to compare the functional and surgical outcomes of patients treated with dynamic compression plating versus those treated with interlocking nailing to determine the most effective approach for managing humeral shaft fractures.

METHODOLOGY & MATERIALS

This cross-sectional study in Department of Orthopaedic Surgery, Bangabandhu Sheikh Mujib Medical University, Bangladesh, conducted from [11/12/2022] to [20/12/2023]. Sixty participants were carefully selected using purposive sampling, ensuring strict adherence to predefined inclusion and exclusion criteria. Before participation, the study's objectives, aims, and procedures were thoroughly explained to all participants, and written informed consent was obtained. Baseline demographic information was recorded for each patient, with a strong emphasis on maintaining data confidentiality. The study received ethical approval from the institutional ethics committee.

Participants were divided into two distinct groups:

- **Group A (N=30):** Comprised of 30 patients with humerus diaphyseal fractures treated with dynamic compression plating.
- **Group B (N=30):** Included 30 patients with humerus diaphyseal fractures treated with interlock nailing.

Inclusion Criteria:

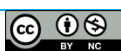- Patients with humerus shaft fractures treated with standard surgical techniques.
- Patients aged above 18 years.

Exclusion Criteria:

- Patients with additional fractures in the same limb.
- Patients aged above 80 years.
- Patients with an open wound on the arm associated with a humerus diaphyseal fracture on the same arm.
- Patients with preoperative neurovascular injury.

Management Protocol:

The study assessed various factors, including age, gender, fracture side, blood loss, operation time, Constant Murley score, Mayo Elbow Performance Index, union, shoulder stiffness, and neurovascular deficit. Patients were prepared on the morning of surgery, receiving a single dose of preoperative antibiotics following a test dose. Surgery was



conducted under strict aseptic conditions, and preoperative consent was obtained.

Dynamic Compression Plating Procedure:

Under appropriate anesthesia, the patient was positioned either prone with the arm at a 90° angle, the elbow bent, and the forearm hanging over the table edge, or laterally with the affected side uppermost [16]. A longitudinal skin incision was made along the midline of the posterior arm, extending from 9 cm below the acromion to the olecranon fossa [17]. The triceps fascia was incised, and the radial nerve was carefully identified and mobilized proximally and distally [18]. The triceps muscle was stripped off the periosteum to expose the fracture site. The fracture ends were freshened, reduced, and held with bone clamps or a lag screw before applying the dynamic compression plate [19].

Interlock Nailing Procedure

Under appropriate anesthesia, the patient is positioned supine on a fracture table with a sandbag placed under the ipsilateral shoulder. The upper limb is then prepared and draped to allow free movement [20]. Utilizing a lateral deltoid-splitting approach with image intensifier assistance, an entry point is created just medial to the greater tuberosity of the proximal humerus, at the junction between the articular surface of the humeral head and the greater tuberosity, using a K-wire, which is then advanced into the medullary canal [21]. Following deltoid splitting, the rotator cuff is exposed, and the supraspinatus tendon is divided [22]. An entry point reamer is guided over the K-wire to enlarge the entry site by 0.45 cm. A guide wire is introduced through the entry point and passed into the distal fragment from the proximal fragment after closed fracture reduction, all under C-arm image intensifier guidance. Progressive reaming is performed over the guide wire up to 1 mm larger than the desired nail size [23]. The appropriate nail, carefully selected to avoid splintering the distal fragment, is mounted on the jig and inserted along the guide wire while maintaining the fracture reduction. The nail is advanced carefully to ensure it does not protrude through the proximal humerus [24]. Distal locking is performed in the anteroposterior plane. A stab incision is made on the anterior aspect of the arm under image guidance, and the brachialis and biceps muscles are split to expose the bone surface [25]. The appropriate drill bit is used under image intensifier guidance, and the distal screws are inserted. Proximal locking is completed using a proximal jig mounted on the nail, with careful attention to avoid injury to the axillary nerve. The proximal locking is carried out in a lateral-to-medial direction [24].

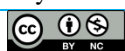Statistical Analysis

All data were systematically organized into appropriate tables or graphs based on relevance, accompanied by clear descriptions to facilitate understanding. Statistical analyses were conducted using the Statistical Package

for Social Science (SPSS, version 26) software on the Windows platform. Continuous variables were expressed as mean \pm standard deviation (SD), while categorical variables were represented as frequencies and percentages. Group comparisons for continuous variables were carried out using the Student's t-test, and the Chi-Square test was applied for categorical variables. Statistical significance was determined at a 95% confidence interval, with a p-value of less than 0.05 considered indicative of significance.

RESULT

A prospective observational study conducted at a tertiary care center involved 60 patients randomly assigned to two groups using computer-generated coded envelopes. Group A consisted of 30 patients with humeral diaphyseal fractures treated using dynamic compression plating, while Group B comprised 30 patients whose humeral diaphyseal fractures were managed with interlocking nailing. Table 1 presents the sociodemographic characteristics of study subjects in Groups A and B, consisting of 30 individuals. The age distribution shows that most participants in both groups are 30 years or younger (46.67% in Group A and 53.33% in Group B). The mean ages are 34.47 \pm 8.41 years for Group A and 32.82 \pm 10.53 years for Group B, with no statistically significant difference ($p=0.314$). Gender distribution reveals a higher proportion of males in both groups (63.33% in Group A and 73.33% in Group B), though this difference is not statistically significant ($p=0.516$). Figure 1 illustrates the percentage distribution of fracture sides (left vs. right) between two groups. In Group A, 43.33% of fractures occurred on the left side, while 56.67% were on the right. Conversely, Group B exhibited a lower incidence of left-sided fractures at 36.67% but a higher incidence on the right side at 63.33%. It shows that fractures in both groups are more common on the right side, with Group B showing a slightly higher predilection for right-sided fractures than Group A. The data presented in Tables 2 to 5 comprehensively compare two study groups on key postoperative outcomes. Table 2 highlights a marked difference in blood loss between the groups. Group A experienced significantly higher blood loss (249.61 \pm 31.72 ml) compared to Group B (88.38 \pm 18.94 ml), with a highly significant p-value of <0.001 . This indicates that Group B had a notably better blood management outcome. Table 3 compares operative times, revealing that Group B had a slightly shorter mean operative time (138.55 \pm 13.72 minutes) compared to Group A (143.35 \pm 15.45 minutes), though this difference was not statistically significant ($p = 0.561$). In terms of functional outcomes, Table 4 shows that Group A had a superior Constant Murley score (94.67 \pm 2.13) compared to Group B (88.17 \pm 4.73), with a significant p-value of <0.001 , indicating better shoulder function in Group A. Table 5 presents the Mayo elbow performance index, where no significant difference was observed between the groups. Group A



had a mean score of 90.66 ± 3.89 , while Group B scored 91.48 ± 3.26 , with a p-value of 0.698, suggesting comparable elbow performance across both groups. Figure 2 illustrates that union was achieved in 86.67% of patients who underwent dynamic compression plating, compared to 83.33% of those who received interlock nailing. Shoulder stiffness was observed in 13.33% of patients treated with dynamic compression plating, while 86.67% of these patients did not experience shoulder stiffness. In contrast, 26.67% of

patients who underwent interlock nailing had shoulder stiffness, with 73.33% not experiencing this complication. A significant difference in shoulder stiffness between the two treatment methods was noted, with a p-value of 0.034 (Figure 3). Additionally, Figure 4 indicates that 10% of patients treated with dynamic compression plating had a neurovascular deficit, whereas only 3.33% of patients treated with interlock nailing experienced this issue.

Table-1: Sociodemographic Status of the study subjects

Variables	Group A (N=30)		Group B (N=30)		p-value
	N	%	N	%	
Age range (in years)					
≤30	14	46.67	16	53.33	0.314
31-40	7	23.33	5	16.67	
41-50	5	16.67	4	13.33	
51-60	3	10.00	2	6.67	
>60	1	3.33	3	10.00	
Mean±SD	34.47±8.41		32.82±10.53		
Gender					
Male	19	63.33	22	73.33	0.516
Female	11	36.67	8	26.67	

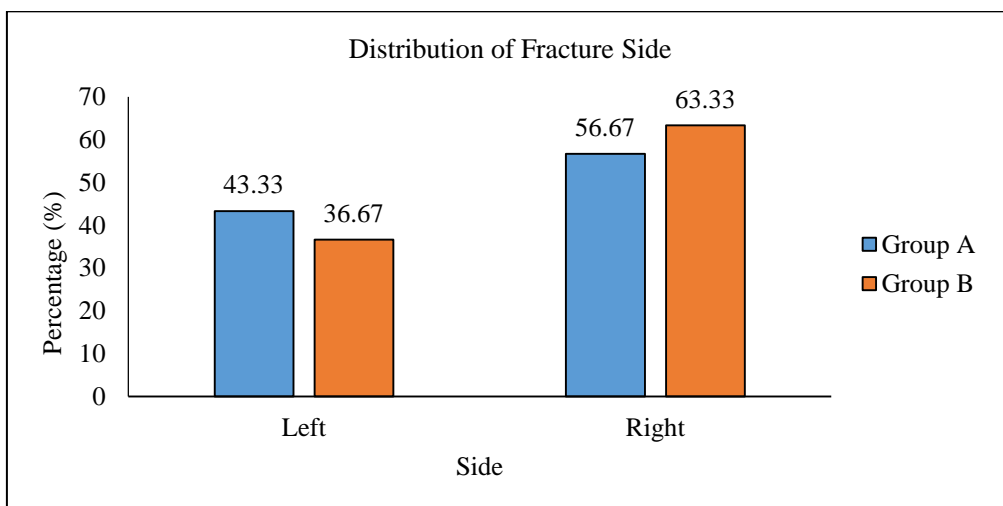


Figure-1: Distribution of study subjects according to the side.

Table-2: Distribution of blood loss between study groups

Blood loss (ml)	Group A (N=30)		Group B (N=30)		p-value
	N	%	N	%	
<100	0	0.00	23	76.67	<0.001
100-200	9	30.00	7	23.33	
>200	21	70.00	0	0.00	
Mean±SD	249.61±31.72		88.38±18.94		

Table-3: Comparison of operative time between study groups

Operative time (min)	Group A (N=30)		Group B (N=30)		p-value
	N	%	N	%	
≤120	3	10.00	4	13.33	0.561
120-150	17	56.67	20	66.67	
>150	10	33.33	6	20.00	
Mean±SD	143.35±15.45		138.55±13.72		



Table-4: Constant Murley score between study groups

Constant Murley score	Group A (N=30)		Group B (N=30)		p-value
	N	%	N	%	
≤80	0	0.00	7	23.33	<0.001
81-90	7	23.33	17	56.67	
>90	23	76.67	6	20.00	
Mean±SD	94.67±2.13		88.17±4.73		

Table-5: Mayo elbow performance index between study groups

Performance index	Group A (N=30)		Group B (N=30)		p-value
	N	%	N	%	
≤90	16	53.33	18	60.00	0.698
91-95	11	36.67	8	26.67	
96-100	3	10.00	4	13.33	
Mean±SD	90.66±3.89		91.48±3.26		

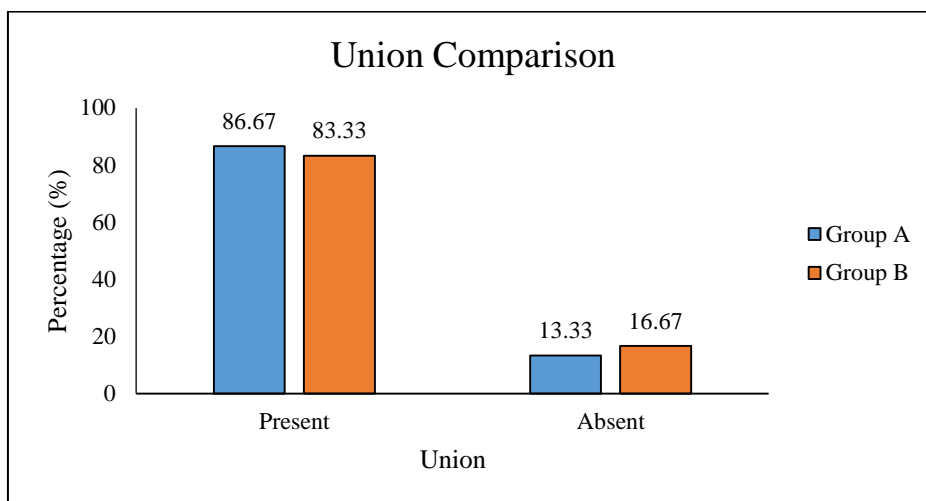


Figure-2: Comparison of union between study groups

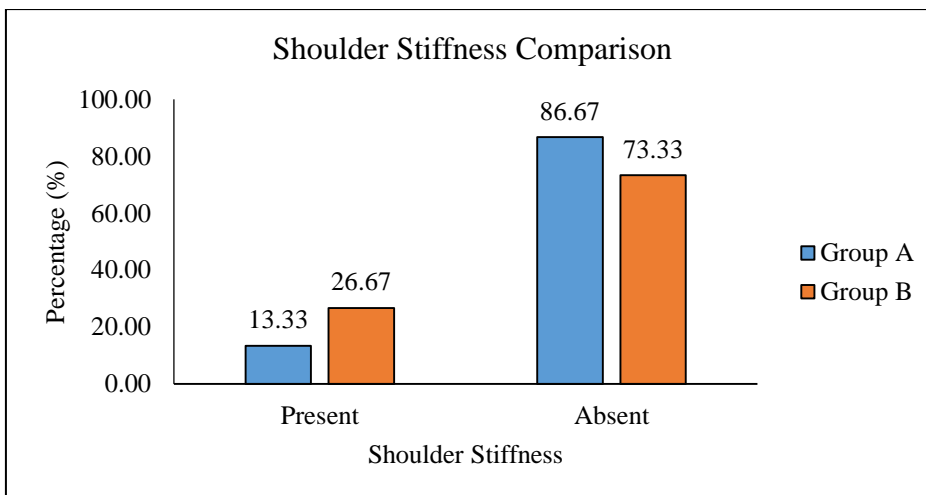


Figure-3: Comparison of shoulder stiffness between study groups

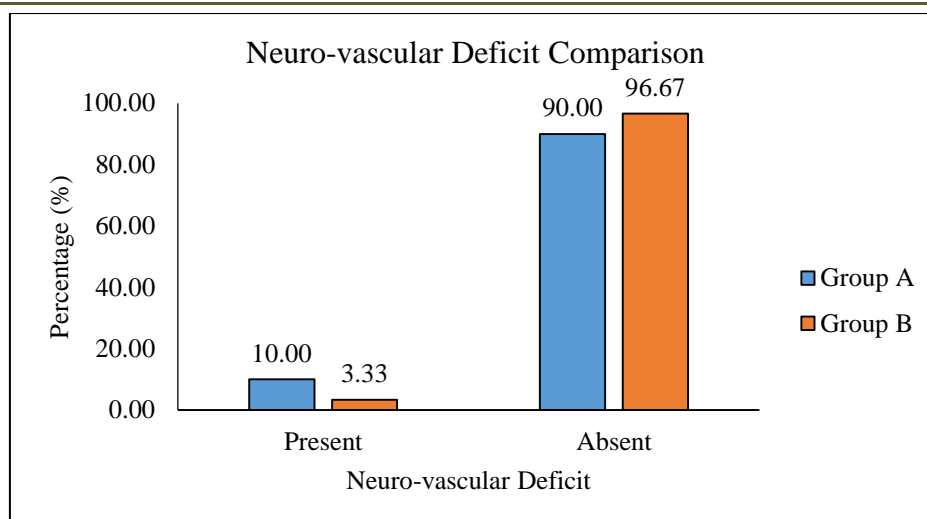


Figure-4: Comparison neuro-vascular deficit between study groups

DISCUSSION

A cross-sectional analytical study compared the functional and surgical outcomes of patients treated with dynamic compression plating versus those treated with interlocking nailing to determine the most effective approach for managing humeral shaft fractures in this study. In this study, the age distribution revealed that most participants in both groups were 30 years or younger, with 46.67% in the dynamic compression plating group and 53.33% in the interlock nailing group. The mean age was 34.47 ± 8.41 years for the dynamic compression plating group and 32.82 ± 10.53 years for the interlock nailing group. Nehate *et al.* (2021) found in their comparative study of dynamic compression plating versus interlock nailing for humerus shaft fractures that 73% of patients were in their 30s and 40s, while 27% were over 40 years old [26]. Regarding gender distribution, a higher proportion of males was observed in both groups, with 63.33% in the dynamic compression plating group and 73.33% in the interlock nailing group. Modi *et al.* (2015) reported similar findings in their comparative study, noting that 77% of participants were male and 23% were female [27]. Fracture location analysis showed that 43.33% of fractures occurred on the left side in the dynamic compression plating group, while 56.67% were on the right. In contrast, the interlock nailing group had a lower incidence of left-sided fractures (36.67%) and a higher incidence on the right side (63.33%). This is consistent with Singh *et al.* (2016), who found that 63.33% of fractures in their study were on the right side [28]. In terms of blood loss, the dynamic compression plating group experienced an average loss of 249.61 ± 31.72 ml, compared to 88.38 ± 18.94 ml in the interlock nailing group. Specifically, 9 (30%) patients in the dynamic compression plating group lost between 100-200 ml, while 21 (70%) lost more than 200 ml. In the interlock nailing group, 23 (76.67%) lost less than 100 ml, and 7 (23.33%) lost between 100-200 ml. This significant difference in blood loss between the two methods was reflected in a p-value of <0.001 . Kulkarni

et al. (2012) also reported a significant difference, with mean blood losses of 20 ml for interlock nailing and 232 ml for dynamic compression plating [29]. The mean operative time was 145.41 ± 14.36 minutes for dynamic compression plating and 140.71 ± 12.59 minutes for interlock nailing. In the dynamic compression plating group, 3 (10%) patients had operative times under 120 minutes, 17 (56.67%) had times between 120-150 minutes, and 10 (33.33%) had times over 150 minutes. For interlock nailing, 4 (13.33%) patients had operative times under 120 minutes, 20 (66.67%) were between 120-150 minutes, and 6 (20%) were over 150 minutes. No significant difference was found in operative time between the two groups ($p=0.561$). Nehate *et al.* (2021) found that the operative time was significantly longer for plating (123.8 minutes) than for nailing (58.4 minutes) due to the more extensive dissection required for plating [26]. Among the studied patients, 26 (86.67%) in the dynamic compression plating group achieved union, with 4 (13.33%) experiencing non-union. In the interlock nailing group, 25 (83.33%) had a union, while 5 (16.67%) had non-union. Modi *et al.* (2015) observed no cases of non-union in the dynamic compression plating group, whereas the interlock nailing group had a non-union incidence of 7.7% [27]. In the interlock nailing group, shoulder stiffness was present in 4 (13.33%) patients treated with dynamic compression plating, compared to 8 (26.67%). The difference in shoulder stiffness between the two groups was statistically significant ($p=0.034$). Singh *et al.* (2016) reported that shoulder stiffness was more common in the interlock nailing group, with 10 cases, compared to none in the dynamic compression plating group [28]. Neurovascular deficits were observed in 3 (10%) patients treated with dynamic compression plating, whereas 1 (3.33%) patient in the interlock nailing group experienced such deficits. Naveen *et al.* (2013) noted no cases of postoperative radial nerve palsy in the dynamic compression plating group, but two patients in the interlock nailing group developed neuropraxia,

which gradually resolved [30]. The Constant-Murley score for shoulder function averaged 94.67 ± 2.13 in the dynamic compression plating group and 88.17 ± 4.73 in the interlock nailing group. In the dynamic compression plating group, 7 (23.33%) patients scored between 81-90, while 23 (76.67%) scored above 90. In the interlock nailing group, 7 (23.33%) scored below 80, 17 (56.67%) scored between 81-90, and 6 (20%) scored above 90. The difference in Constant-Murley scores between the two groups was significant ($p < 0.001$). Lastly, the Mayo Elbow Performance Index (MEPI) was 90.66 ± 3.89 in the dynamic compression plating group and 91.48 ± 3.26 in the interlock nailing group. Among the dynamic compression plating group, 16 (53.33%) had a MEPI below 90, 11 (36.67%) scored between 91-95, and 3 (10%) scored between 96-100. In the interlock nailing group, 18 (60%) scored below 90, 8 (26.67%) scored between 91-95, and 4 (13.33%) scored between 96-100. No significant difference in MEPI was found between the two groups ($p = 0.698$). Kulkarni *et al.* (2012) found similar results, with no significant differences in functional outcomes between the two methods as measured by the American Shoulder and Elbow Surgeons score and range of motion after eight months of follow-up [29]. Nehate *et al.* (2021) also reported no significant differences in functional outcomes between the groups [26].

Limitations of the study: Every hospital-based study has inherent limitations, and this study is no different. The primary constraints include the following: the findings may not be broadly applicable at a national or global level due to the study's reliance on a single tertiary care center; the sample size was relatively modest in comparison to other research; the short duration of the trial hindered the comprehensive assessment of complications and mortality; and there was no extended follow-up with patients.

CONCLUSION AND RECOMMENDATIONS

In this prospective study, various clinical parameters were assessed in patients. Most participants were under 30 years old, with males being more frequently affected than females. Fractures on the right side were more common than on the left. Dynamic compression plating was associated with longer operative time, more significant blood loss, and a higher union rate. Neurovascular deficits were lower with interlock nailing compared to dynamic compression plating. However, the Constant Murley score was significantly higher for dynamic compression plating, indicating more pronounced shoulder stiffness in patients treated with interlock nailing, which suggests reduced shoulder function postoperatively. The Mayo elbow performance score was also higher in the dynamic compression plating group, although this difference was not statistically significant. Dynamic compression plating should be the gold standard for the surgical treatment of humeral shaft fractures.

Funding: No funding.

Conflict of interest: No conflict of interest.

REFERENCES

- Sahu RL, Ranjan R, Lal A. Fracture union in closed interlocking nail in humeral shaft fractures. *Chinese Medical Journal*. 2015 Jun 5; 128(11):1428-32.
- Hasan A, Mondol AR, Akter MS, Rahman M, Miah MS. Epidemiology of Fractures with Indoor Patients in Bangabandhu Sheikh Mujib Medical College, Faridpur, Bangladesh. *Acta Scientific Orthopaedics*. 2022 Oct; 5(10):74-8.
- Böhler L. Conservative treatment of fresh closed fractures of the shaft of the humerus. *Journal of Trauma and Acute Care Surgery*. 1965 Jul 1; 5(4):464-8.
- Sarmiento A, Zagorski JB, Zych GA, Latta LL, Capps CA. Functional bracing for the treatment of fractures of the humeral diaphysis. *JBJS*. 2000 Apr 1; 82(4):478.
- Koch PP, Gross DF, Gerber C. The results of functional (Sarmiento) bracing of humeral shaft fractures. *Journal of shoulder and elbow surgery*. 2002 Mar 1; 11(2):143-50.
- Schemitsch EH, Bhandari M. Fractures of the diaphyseal humerus. *Skeletal trauma*, 3rd ed. Toronto: WB Saunders. 2001:1481-511.
- Rommens PM, Verbruggen J, Broos PL. Retrograde locked nailing of humeral shaft fractures. A review of 39 patients. *The Journal of Bone & Joint Surgery British Volume*. 1995 Jan 1; 77(1):84-9.
- Ulrich C. Surgical treatment of humeral diaphyseal fractures. *Musculoskeletal Trauma Series: Humerus*. Butterworth Heinemann. 1996:129-43.
- Fouk DA, Szabo RM. Diaphyseal humerus fractures: natural history and occurrence of nonunion. *Orthopedics*. 1995 Apr 1; 18(4):333-5.
- HEALY WL, WHITE GM, MICK CA, BROOKER JR AF, WEILAND AJ. Nonunion of the humeral shaft. *Clinical Orthopaedics and Related Research (1976-2007)*. 1987 Jun 1; 219:206-13.
- Jupiter JB, von Deck M. Ununited humeral diaphyses. *Journal of Shoulder and Elbow Surgery*. 1998 Nov 1; 7(6):644-53.
- Heim D, Herkert F, Hess P, Regazzoni P. Surgical treatment of humeral shaft fractures—the Basel experience. *Journal of Trauma and Acute Care Surgery*. 1993 Aug 1; 35(2):226-32.
- Robinson CM, Bell KM, McQueen MM. Locked nailing of humeral shaft fractures. Experience in Edinburgh over a two-year period. *The Journal of Bone & Joint Surgery British Volume*. 1992 Jul 1; 74(4):558-62.



14. Paris H, Tropiano P, Chaudet H, Poitout DG. Fractures of the shaft of the humerus: systematic plate fixation. Anatomic and functional results in 156 cases and a review of the literature. *Revue de chirurgie orthopedique et reparatrice de l'appareil moteur*. 2000 Jun 1; 86(4):346-59.
15. Wali MG, Baba AN, Latoos IA, Bhat NA, Baba OK, Sharma S. Internal fixation of shaft humerus fractures by dynamic compression plate or interlocking intramedullary nail: a prospective, randomised study. *Strategies in trauma and limb reconstruction*. 2014 Nov; 9:133-40.
16. Singh S, Gupta S, Kaushik SK. Comparative Study between Use of Interlock Nailing and Dynamic Compression Plate for the Management of Diaphyseal Fracture of Humerus. *INTERNATIONAL JOURNAL OF SCIENTIFIC STUDY*. 2018 Apr 26;6(1):52-8.
17. Lazcarro JH, Pizarro DL. A comparison of the prevalence of radial nerve lesion after fixation of humeral shaft fractures with dynamic compression plate Versus intramedullary nailing. *Acta ortopédica mexicana*. 2008; 22(5):287-91.
18. Gamal Hosny AM, Mohammed Anwar G, Mohammed H. Interlocking nailing versus plating of humeral shaft fractures.
19. Meekers FS, Broos PL. Operative treatment of humeral shaft fractures, the Leuven experience. *Acta orthopaedica belgica*. 2002 Dec 1; 68(5):462-70.
20. Raghavendra S, Bhalodiya HP. Internal fixation of fractures of the shaft of the humerus by dynamic compression plate or intramedullary nail: A prospective study. *Indian journal of orthopaedics*. 2007 Jul; 41(3):214.
21. Putti AB, Uppin RB, Putti BB. Locked intramedullary nailing versus dynamic compression plating for humeral shaft fractures. *Journal of Orthopaedic Surgery*. 2009 Aug; 17(2):139-41.
22. Stern PJ, Mattingly DA, Pomeroy DL, Zenni Jr EJ, Kreig JK. Intramedullary fixation of humeral shaft fractures. *JBJS*. 1984 Jun 1; 66(5):639-46.
23. Gamal Hosny AM, Mohammed Anwar G, Mohammed H. Interlocking nailing versus plating of humeral shaft fractures.
24. Ingman AM, Waters DA. Locked intramedullary nailing of humeral shaft fractures. Implant design, surgical technique, and clinical results. *The Journal of Bone & Joint Surgery British Volume*. 1994 Jan 1; 76(1):23-9.
25. Heineman DJ, Poolman RW, Nork SE, Ponsen KJ, Bhandari M. Plate fixation or intramedullary fixation of humeral shaft fractures: An updated meta-analysis. *Acta Orthopaedica*. 2010 Apr 1; 81(2):216-23.
26. Nehate YB, Agarwal RH. Comparative study between dynamic compression plating versus interlock nailing in treatment of fracture of shaft of humerus. *MedPulse Int J Orthop*. 2021; 20(1):23-8.
27. Modi N, Pundkar GN. Comparative study of functional outcome of dynamic compression plating with Intramedullary Interlocking nailing in close fracture shaft of humerus in adults. *J Res Med Dent Sci*. 2015 Oct 1; 3(4):298-302.
28. Singh P, Gandhi V, Bansal D. Comparative study of compression plating vs interlocking nail in fracture shaft of humerus. *International Journal of Contemporary Medical Research*. 2016;3(11):3385-8.
29. Kulkarni SG, Varshneya A, Jain M, Kulkarni VS, Kulkarni GS, Kulkarni MG, Kulkarni RM. Antegrade interlocking nailing versus dynamic compression plating for humeral shaft fractures. *Journal of Orthopaedic Surgery*. 2012 Dec; 20(3):288-91.
30. Naveen PR, Chaitanya PR. Comparative study between the dynamic compression plating (DCP) and the intramedullary interlocking nailing in diaphyseal fractures of the humerus in adults. *Journal of evolution of medical and dental sciences*. 2013 Nov 11; 2(45):8704-13.