

Case Report

DOI: 10.62046/gijams.2024.v02i03.002

An Intrabronchial Foreign Body Revealed by Bronchiectasis (Bone Fragment)

Khalil Ghebouli¹, Karim Meskouri¹, Mohammed Amine Kecir², Mehdi Belbekri², Sedik Merouani², Houda Amrane² and Kenza Bendjoudi³

¹Department of Thoracic Cardiovascular and Organ Transplantation, University Hospital Mustapha, Algiers, Algeria

²Department of Thoracic Surgery, University Hospital Ben Badis, Constantine, Algeria

³Department of Anesthesia, University Hospital Mustapha, Algiers, Algeria

*Corresponding Author: Khalil Ghebouli | Received: 16.03.2024 | Accepted: 20.04.2024 | Published: 18.05.2024

Abstract: Tracheobronchial foreign bodies (FB) by inhalation accidental are serious incidents and particularly common in children. In adults, they are less frequent, very often unrecognized and therefore diagnostic often difficult. Passed unnoticed or neglected, these intrabronchial FBs are responsible for repeated respiratory infections, bronchiectasis, which can lead to destruction of the pulmonary parenchyma. We report a case of a neglected foreign body (bone fragment) present in the bronchus of an adult for 53 years revealed by bronchopulmonary suppurations causing bronchiectasis and treated surgically.

Keywords: Foreign bodies, bone fragment, bronchiectasis, surgery

Citation: Khalil Ghebouli *et al.* An Intrabronchial Foreign Body Revealed by Bronchiectasis (Bone Fragment). Grn Int J Apl Med Sci, 2024 May-Jun 2(3): 88-91.

INTRODUCTION

Inhalation of a food foreign body can be accidental or result from damage to the aerodigestive junction, it can go unnoticed or it can manifest itself by noisy symptoms [1]. Bronchiectasis caused by a foreign body is quite rare in adult.

We report a case of bronchus dilation in an adult on a foreign body (bone fragment) inhaled 43 years ago, on the occasion of the Aid holiday.

CASE REPORT

A 43-year-old, men, non-smoker, who was admitted to our thoracic surgery department, for the management of

bronchiectasis complicated by bronchopulmonary suppuration.

Before this complication, the history of the disease dates back 43 years, date on which the patient reports, at the age of 10, the notion of inhaling a bone fragment during an aid meal.

The clinical symptoms were silent until the onset of a recurring bronchopulmonary suppuration syndrome.

The chest x-ray showed a left basal pulmonary rail image, without highlighting the foreign body (Figure 1).

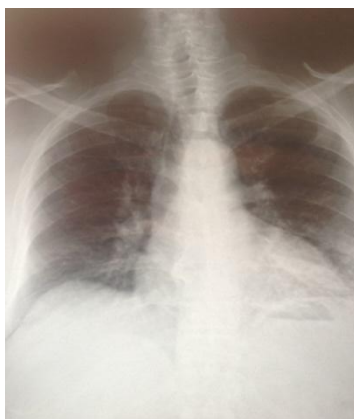

Figure 1: Chest x-ray showing left basal pulmonary rail image

CT scan showed a foreign body of intrabronchial, with bone density involving the left lower lobar bronchus which is partially obstructed with upstream cylindrical

bronchiectasis associated with alveolointerstitial filling of the basal pyramid (Figure 2a, b, c, d)

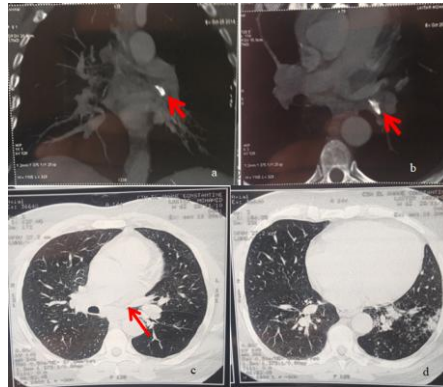


Figure 2a, b, c, d: showing intrabronchial foreign body of the left lower lobar bronchus with cylindrical bronchiectasis

A bronchoscopy performed was unable to visualize the foreign body. After preparation of the patient by respiratory physiotherapy and antibiotic therapy, the patient was operated on by a left posterolateral

thoracotomy passing through the 5th intercostal space. A bronchotomy was carried out allowing the extraction of the foreign body with left lower pulmonary lobectomy (Figure3, 4).

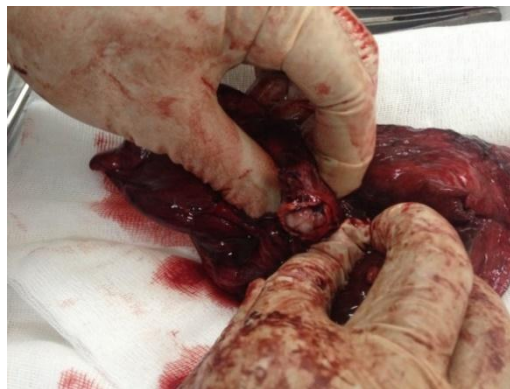

Figure 3: lower left lobectomy

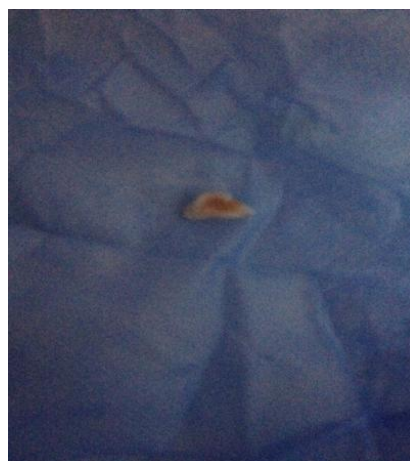

Figure 4: foreign body (bone fragment)

The surgical procedure was completed by the placement of two chest tubes which were removed on day 2 and day 4 (Figure 5).

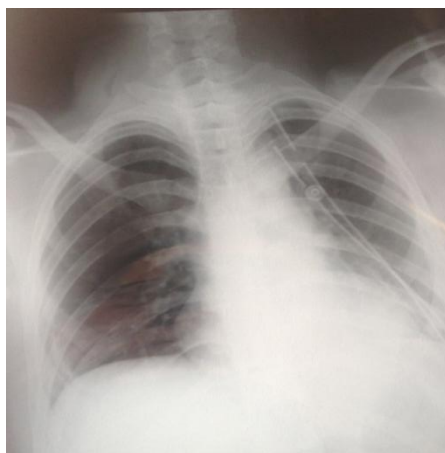


Figure 5: control chest X-ray

The short and long term evolution was without complication. The patient was released from the hospital on day 5 and followed for two years.

DISCUSSION

Inhalation of tracheobronchial foreign bodies is more common in the pediatric between 1 and 3 years of age because of the immaturity of the teeth and larynx and the tendency of these children to explore objects by introducing them into the mouth, especially when they laugh or cry. But it can also concern older children or adults when an ingestion of food or object “mistakes” the respiratory tract, creating a penetration syndrome [2,3].

Inhalation of a foreign food body is accidental; it can be serious and life-threatening. It is more common in children and rare in adults. The diagnosis is often difficult, posing a problem of differential diagnosis [4]. The predominance is male in 2/3 of cases, in adult's food foreign bodies made of pieces of meat, fish bones, vegetables or fruits. They are mainly located at the level of the right bronchial axis due to the straightness of the right main bronchus. In the series by Caidi *et al.* [4], the foreign body was located, in more than half of the cases, at the right main bronchus and preferentially at the intermediate trunk unlike the case of our patient.

The clinical presentation is often acute with a picture of respiratory distress, stridor, asthmatic dyspnea, wheezing; or it can be done remotely at the stage of complications.

The incidence of these increases with the diagnostic delay and the time elapsed before extraction of the FB. The FB can become stuck and cause complications such as: recurrent infectious bronchopneumopathy in the same territory or with atypical presentation, abscess, pleuropneumopathy, obstructive empyema, localized bronchiectasis, total bronchial obstruction (atelectasis), inflammatory reactions which can organize themselves into a real granuloma completely masking the FB during endoscopy [5-7]. Rare cases of

pneumomediastinum, pneumothorax, subcutaneous emphysema or symptoms simulating an asthma attack or “false asthma” responding poorly to treatment or diaphragmatic hernia have been reported in the literature [6,8].

Chest radiography can highlight the radiopaque foreign body as it can be non-specific, images of obstructive emphysema; atelectasis, localized bronchial dilatation, pneumonia and exceptionally pneumothorax or pneumomediastinum can be seen [9]. Chest CT is more precise, it highlights the foreign body as well as its location. Bronchial endoscopy must be performed urgently, for diagnostic and therapeutic purposes. Surgery is rarely indicated and concerns cases of endoscopy failure, as well as unknown foreign bodies with irreversible tracheobronchial destruction [10] as is the case of our patient.

Chronic neglected FB can cause parenchymal destruction, sometimes irreversible, requiring parenchymal sacrifice which can range from simple segmentectomy to pneumonectomy. Caidi *et al.* [4] had operated on 15 cases of intrabronchial ECs after failure of several attempts at bronchoscopic extraction due to inflammatory and granulomatous changes in the bronchus, or because of the incarceration of some FBs in the bronchial wall: these were 1 pneumonectomy for parenchymal destruction, 5 lobectomies, 3 bisegmentectomies, 3 segmentectomies and 3 cases of conservative surgery either by tracheotomy, bronchotomy or pneumotomy.

CONCLUSION

Inhalation of a neglected food foreign body is a rare phenomenon in adults. These intrabronchial foreign bodies are responsible for recurrent respiratory infections, bronchiectasis, which can cause a destruction of the pulmonary parenchyma. The treatment is based on its rapid extraction by bronchoscopy in order to avoid complications and the onset of irreversible parenchymal destruction requiring surgical intervention.



Conflict of interest: None

REFERENCES

1. Ruel M, Haas C, Guivarc'h P. Corps étrangers solides méconnus des voies respiratoires chez l'adulte. *Concours med (Paris)*. 1984;106(45):4416-24.
2. Vithalani PD, Maniyar H. An overlooked bronchial foreign body in adult. *Indian J Otolaryngol Head Neck Surg* 2005;57:335—7.
3. Eren S, Balci AE, Dikici B, *et al*. Foreign body aspiration in children: experience of 1160 cases. *Ann Trop Paediatr* 2003;23:31—7.
4. Caidi M, Kabiri H, Lazrek I, el Maslout A, Ben Osman A. Chirurgie des corps étrangers intrabronchiques. *Annales de Chirurgie*. 2002;127(6):456-60.
5. Benjelloun H, Zaghba N, Bakhatar A, *et al*. Les corps étrangers trachéobronchiques chez l'adulte. *Pan Afr Med J* 2014;19: 220.
6. Messner AH. Pitfalls in the diagnosis of aerodigestive tract foreign bodies. *Clin Pediatr* 1998;37:359—65.
7. Moura e Sá J, Oliveira A, Caiado A, *et al*. Tracheobronchial foreign bodies in adults—Experience of the Bronchology Unit of Centro Hospitalar de Vila Nova de Gaia. *Rev Port Pneumol* 2006;12:31—43.
8. Kane GC, Sloane PJ, McComb B, *et al*. Missed inhaled foreign body in an adult. *Resp Med* 1994;88:551—4.
9. Bacha S, Habibech S, Chabbou A. [Inhalation of unusual metallic foreign body]. *Rev Pneumol Clin*. 2017;73(2):109-10.
10. Jabri H, Arfaoui H, Elkhatabi W, Afif H. Bacterial pneumonia with pleural effusion revealing aspiration of a chicken bone. *Int J Adv Res*. 2018;6(9):593-5.

